Original Article

Cukurova Anestezi ve Cerrahi Bilimler Dergisi

Association of p16 Loss and EZH2 Overexpression with Clinicopathological Characteristics and Prognosis in Gastrointestinal Stromal Tumors

Tuğba Toyran[1], *Kıvılcım Eren Ateş*[1], *Tolga Köşeci*[2], *Uğur Topal*[3], *Cem Kaan Parsak*[3], *Yusuf Kemal Arslan*[4], *Arbil Açıkalın*[1]

[1] Cukurova University Faculty of Medicine, Department of Pathology, Adana, Türkiye
[2] Cukurova University Faculty of Medicine, Department of Oncology, Adana, Türkiye
[3] Cukurova University Faculty of Medicine, Department of General Surgery, Adana, Türkiye
[4] Çukurova University, Faculty of Medicine, Department of Biostatistics, Adana, Türkiye
***Correspondence:** Tuğba Toyran; tugbaolcan@hotmail.com
Cite as: Toyran T, Ateş KE, Köşeci T, Topal U, Parsak CK, Arslan YK, et al. Association of p16 Loss and EZH2 Overexpression with Clinicopathological Characteristics and Prognosis in Gastrointestinal Stromal Tumors. J Cukurova Anesth Surg. 2026;9(3):870-884. doi:10.36516/jocass.1999690
Received: 21.07.2026, **Accepted:** 18.09.2026, **Published:** 30.09.2026, **CC BY-NC 4.0**

Abstract

Aim: Gastrointestinal stromal tumors (GISTs) exhibit markedly heterogeneous clinical behavior that is not fully captured by conventional risk classification systems. This study aimed to evaluate the prognostic significance of loss of p16 expression and of EZH2 overexpression, and to assess their relationship with clinicopathological parameters in GIST. **Methods:** In this retrospective study, 113 GIST cases diagnosed at a single institution between 2016 and 2026 were evaluated. Immunohistochemical expression of p16 and EZH2 was evaluated and correlated with clinicopathological parameters and overall survival using Kaplan-Meier and Cox regression analyses. **Results:** Loss of p16 expression was detected in 34 cases (30.1%), and EZH2 overexpression was detected in 12 cases (10.6%). Both markers were significantly correlated with high mitotic activity, metastasis, multifocality, a high AFIP risk category, and elevated Ki-67 proliferation index ($p<0.001$ for all). EZH2 overexpression was significantly more frequent in cases with p16 loss than in those with preserved p16 expression (26.5% vs. 3.8%, $p = 0.001$). In Kaplan–Meier survival analysis, patients with p16 loss and those with EZH2 overexpression exhibited significantly shorter OS (log-rank $p < 0.001$ and $p = 0.001$, respectively). However, in multivariable Cox regression analysis adjusting for clinicopathological covariates, p16 loss (HR=2.159, p=0.040) and AFIP risk category (HR=1.661, $p<0.001$) remained independent prognostic factors, whereas EZH2 overexpression did not retain independent prognostic significance (HR=1.001, p=0.999). **Conclusions:** Loss of p16 expression is an independent adverse prognostic biomarker in GIST. Although EZH2 overexpression is strongly associated with aggressive clinicopathological features and shorter overall survival in Kaplan–Meier analysis, it does not retain independent prognostic significance after adjustment for established pathological risk factors. The significant association between EZH2 overexpression and p16 loss supports the potential involvement of the EZH2/PRC2-CDKN2A epigenetic pathway in GIST progression and warrants further molecular investigation.

Keywords: EZH2; Gastrointestinal stromal tumor; Immunohistochemistry; p16; Prognosis

1. Introduction

Gastrointestinal stromal tumors (GISTs) are the most common mesenchymal neoplasms of the gastrointestinal tract. Their annual incidence is estimated at 10–15 cases per million population; they may arise anywhere along the gastrointestinal tract, most commonly in the stomach (60–70%) and the small intestine (20–25%).[1,2] GISTs are believed to originate from the interstitial cells of Cajal or mesenchymal precursor cells of similar lineage. Their biological behavior ranges from indolent to highly aggressive, reflecting marked clinical heterogeneity.[3]

The molecular pathogenesis of GIST is primarily driven by gain-of-function mutations in the KIT (CD117) proto-oncogene. First described by Hirota et al. in 1998, these mutations are identified in approximately 75–85% of GISTs.[4] Activating mutations in PDGFRA, a receptor tyrosine kinase closely related to KIT, are found in an additional 10–15% of cases.[5] The remaining 10–15% are classified as wild-type GISTs, lacking KIT and PDGFRA mutations and instead harboring alternative genetic alterations, including mutations in the SDH gene complex, NF1 inactivation, or mutations in BRAF.[6,7]

Histopathologically, GISTs are classified into three major morphological subtypes: spindle cell, epithelioid, and mixed.[1] Immunohistochemically, CD117 (c-KIT) and DOG1 (ANO1) are the principal diagnostic markers, DOG1 is particularly valuable as a complementary marker in CD117-negative or weakly positive tumors.[3,8] Prognostic assessment is primarily based on tumor size, mitotic activity, and anatomical location. These parameters form the basis of the NIH consensus criteria (Fletcher et al., 2002)[9] and the Armed Forces Institute of Pathology (AFIP) classification (Miettinen and Lasota, 2006).[10] More recently, the prognostic significance of KIT and PDGFRA mutation status has been incorporated into the modified Joensuu risk classification, providing a more comprehensive risk stratification system.[11]

A major breakthrough in GIST treatment was the introduction of imatinib mesylate in the early 2000s. In patients with advanced or metastatic disease, imatinib has substantially improved response rates and significantly prolonged overall survival (OS).[12] Nevertheless, primary and secondary resistance to imatinib remain major clinical challenges, underscoring the need for additional prognostic biomarkers that better reflect the underlying tumor biology beyond conventional clinicopathological parameters.

Among the molecules of interest, the p16/CDKN2A tumor suppressor gene plays a pivotal role in cell-cycle regulation. The p16 protein inhibits cyclin-dependent kinases 4 and 6 (CDK4/6), thereby preventing phosphorylation of the retinoblastoma (Rb) protein, blocking the G1/S cell-cycle transition, and suppressing cellular proliferation. Consequently, p16 functions as a key tumor suppressor, and its inactivation represents an early event in the development of many human malignancies.[13] Previous studies in GIST have shown that loss of p16 expression is associated with tumor progression and aggressive biological behavior. However, reported frequencies vary considerably (40–70%), largely because of differences in immunohistochemical (IHC) scoring systems and cutoff values.[14-17]

Epigenetic regulation has emerged as a major focus of cancer research over the past decade. Enhancer of Zeste Homolog 2 (EZH2), the catalytic subunit of the Polycomb Repressive Complex 2 (PRC2), mediates the trimethylation of histone H3 at lysine 27 (H3K27me3), resulting in chromatin condensation and transcriptional silencing of target genes.[18,19] EZH2 overexpression has been reported in numerous malignancies, including breast, prostate, lung, and colorectal carcinomas as well as lymphomas, and is frequently associated with poor clinical outcomes.[20,21] Experimental studies have identified the p16/CDKN2A promoter as one of the major epigenetic targets of EZH2, and inhibition of EZH2 has been shown to restore p16 and p21 expression in several tumor models.[22,23] However, studies investigating the role of EZH2 in GIST remain limited.

In this study, we retrospectively analyzed 113 patients diagnosed with GIST at our institution over a 10-year period. IHC was used to evaluate p16 loss and EZH2 overexpression, and associations between these alterations and clinicopathological characteristics, including tumor size, mitotic activity, histological subtype, necrosis, metastasis, AFIP risk category, and patient prognosis, were investigated. In addition, we examined the relationship between p16 and EZH2 expression to explore their potential interaction within the context of epigenetic regulation.

2. Materials and Methods

2.1. Study Population

This retrospective study included 113 patients diagnosed with GIST between 2016 and 2026 at the Department of Pathology, Çukurova University Faculty of Medicine. Cases were identified through a review of the pathology archive and the hospital information management system. Patients with insufficient tumor tissue for IHC analysis, inadequate tissue fixation, technical artifacts affecting interpretation, or incomplete clinicopathological data were excluded.

Demographic, clinical, and histopathological data, including age, sex, tumor size, tumor location, mitotic rate, AFIP risk category, distant metastasis, histological subtype, Ki-67 proliferation index, necrosis, and multifocality, were retrieved from pathology reports and medical records. Histopathological classification and AFIP risk stratification were performed according to the WHO Classification of Tumours of the Digestive System (5th edition).[1]

2.2. Immunohistochemical Analysis

IHC staining was performed on 4-μm sections prepared from formalin-fixed, paraffin-embedded tissue blocks using a fully automated staining platform (Ventana BenchMark Ultra; Roche Diagnostics, Tucson, AZ, USA). A monoclonal anti-p16 antibody (clone JC8) was used to evaluate p16 (CDKN2A) expression, whereas EZH2 expression was assessed using an anti-EZH2 antibody (ab227648, 1:100; Abcam).

2.3. Evaluation of Immunohistochemical Staining

p16 expression was evaluated by assessing the nuclear and cytoplasmic staining. At least 500 tumor cells were examined in each case, and the percentage of positively stained cells was recorded. According to the cutoff value reported in the literature, cases showing staining in <20% of tumor cells were classified as exhibiting loss of p16 expression, whereas those with staining in ≥20% of tumor cells were classified as having preserved p16 expression.[14] (Figure 1A)

EZH2 expression was evaluated exclusively by nuclear staining. Staining intensity was graded as weak (1+), moderate (2+), or strong (3+). Cases demonstrating moderate-to-strong (≥2+) nuclear staining in more than 10% of tumor cells were classified as EZH2-positive, whereas all other cases were classified as EZH2-negative.[24] (Figure 1B)

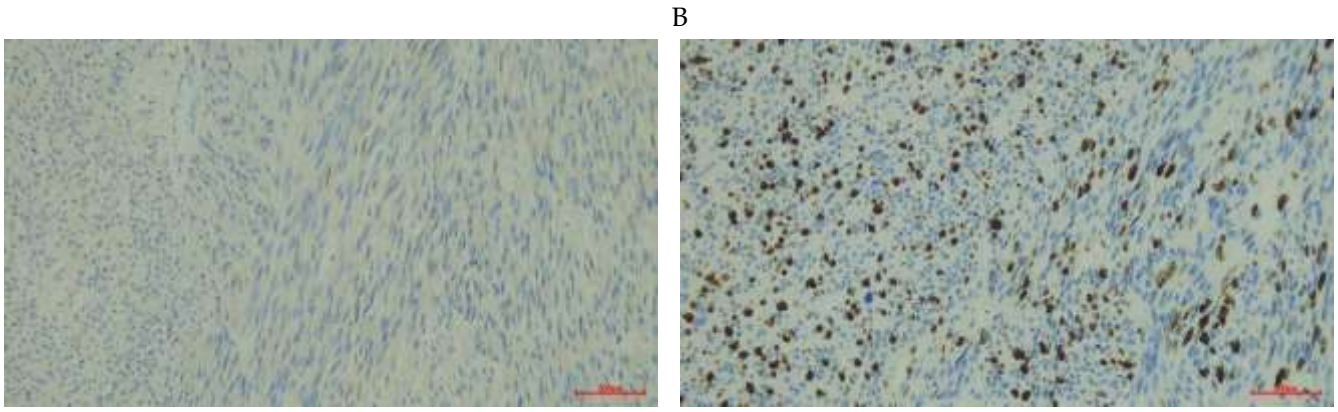

Figure 1. Immunohistochemical expression of p16 and EZH2 in gastrointestinal stromal tumor. (A) Loss of p16 expression in tumor cells, with no nuclear or cytoplasmic staining (IHC, ×200). (B) EZH2 overexpression, showing strong nuclear staining in more than 10% of tumor cells (IHC, ×200).

2.4. Ethical Considerations

The study protocol was approved by the Non-Interventional Clinical Research Ethics Committee of the Faculty of Medicine, Çukurova University, at its 168th meeting (July 10, 2026; Decision No. 69). Owing to the retrospective design of the study and the use of anonymized patient data, the requirement for informed consent was waived. All procedures were conducted in accordance with the ethical principles of the Declaration of Helsinki.

2.5. Statistical Analysis

Categorical variables were presented as frequencies (n) and percentages (%). Visual and analytical methods were used to assess the normality of continuous variables. Continuous variables with normal distribution were summarized as mean±standard deviation and non-normally distributed variables were presented as median and interquartile range (Q1-Q3). Student's t-test was employed for normally distributed data and the Mann-Whitney U test for non-normally distributed data to compare continuous variables between two independent groups. Statistical analyses for categorical variables were performed using Pearson's chi-square test; when expected cell counts were low, Fisher's exact test was used. The Kaplan-Meier method was used to estimate survival curves and the log-rank test was used to compare survival between groups. First, a univariable Cox regression analysis was performed to identify potential risk factors for mortality. An adjusted model to identify independent predictors was obtained from a multivariable Cox regression analysis that included variables that were statistically significant in the univariable analysis, together with age and sex as potential biological confounders. For all statistical analyses, the significance level was set at $p < 0.05$. All statistical analyses were performed using IBM SPSS 20 (Armonk, NY. USA: IBM Corp.).

3. Results

A total of 113 patients with GIST were included in the study. The demographic, clinicopathological, and IHC characteristics of the study cohort are summarized in Table 1. Sixty patients (53.1%) were male and 53 (46.9%) were female. Most tumors were of the spindle cell subtype (96 cases, 85.0%); CD117 and DOG1 positivity were observed in 92.0% and 97.3% of cases, respectively. EZH2 overexpression was detected in 10.6% of cases, whereas loss of p16 expression was identified in 30.1%. According to the AFIP classification, 38.0% of patients were at high risk (Groups 6A and 6B).

Table 1: Demographic, Clinicopathological, and Immunohistochemical Characteristics of Patients with Gastrointestinal Stromal Tumors

		n	%
Gender	Male	60	53.1
	Female	53	46.9
Tumor size (cm)	≤2	9	8.0
	> 2 to ≤ 5	22	19.5
	> 5 to ≤ 10	47	41.6
	> 10	35	31.0
CD117 expression	negative	9	8.0
	positive	104	92.0
DOG1 expression	negative	3	2.7
	positive	110	97.3
EZH2 expression	negative	101	89.4
	positive	12	10.6
Loss of p16 expression	negative	79	69.9
	positive	34	30.1
Histological subtype	Spindle cell	96	85.0
	Epithelioid	10	8.8
	Mixed	7	6.2
Mitotic count (mitoses/5 mm2)	≤5	64	56.6
	>5	49	43.4
Survival status	Alive	73	64.6
	Dead	40	35.4
Metastatic status	None	74	65.5
	Unifocal	20	17.7
	Multifocal	19	16.8
AFIP risk category	1	9	8.0
	2	15	13.3
	3a	22	19.5
	3b	18	15.9
	5	6	5.3
	6a	25	22.1
	6b	18	15.9
Surgical resection	Absent	8	7.1
	Present	105	92.9
Multifocality	Absent	88	77.9
	Present	25	22.1
Tumor necrosis	Absent	51	45.1
	Present	62	54.9

Table 2: Association of p16 Loss and EZH2 Overexpression with Clinicopathological Characteristics in Gastrointestinal Stromal Tumors

		Loss of p16 expression		p	EZH2 expression		p
		negative	positive		negative	positive	
Gender	Male	43(54.4)	17(50)	0.665	56(55.4)	4(33.3)	0.147
	Female	36(45.6)	17(50)		45(44.6)	8(66.7)	
Tumor size (cm)	≤2	9(11.4)	0(0)	<0.001	9(8.9)	0(0)	0.140
	> 2 to ≤ 5	22(27.8)	0(0)		22(21.8)	0(0)	
	> 5 to ≤ 10	39(49.4)	8(23.5)		41(40.6)	6(50)	
	> 10	9(11.4)	26(76.5)		29(28.7)	6(50)	
CD117 expression	negative	5(6.3)	4(11.8)	0.328	8(7.9)	1(8.3)	0.960
	positive	74(93.7)	30(88.2)		93(92.1)	11(91.7)	
DOG1 expression	negative	3(3.8)	0(0)	0.249	3(3)	0(0)	0.545
	positive	76(96.2)	34(100)		98(97)	12(100)	
EZH2 expression	negative	76(96.2)	25(73.5)	0.001	-	-	
	positive	3(3.8)	9(26.5)		-	-	
Histological subtype	Spindle cell	70(88.6)	26(76.5)	0.097	87(86.1)	9(75)	0.084
	Epithelioid	4(5.1)	6(17.6)		7(6.9)	3(25)	
	Mixed	5(6.3)	2(5.9)		7(6.9)	0(0)	
Mitotic count (mitoses/5 mm2)	≤5	54(68.4)	10(29.4)	<0.001	64(63.4)	0(0)	<0.001
	>5	25(31.6)	24(70.6)		37(36.6)	12(100)	
Survival status	Alive	62(78.5)	11(32.4)	<0.001	70(69.3)	3(25)	0.004
	Dead	17(21.5)	23(67.6)		31(30.7)	9(75)	
Metastatic status	None	61(77.2)	13(38.2)	<0.001	73(72.3)	1(8.3)	<0.001
	Unifocal	9(11.4)	11(32.4)		18(17.8)	2(16.7)	
	Multifocal	9(11.4)	10(29.4)		10(9.9)	9(75)	
AFIP risk category	1	9(11.4)	0(0)	<0.001	9(8.9)	0(0)	<0.001
	2	15(19)	0(0)		15(14.9)	0(0)	
	3a	22(27.8)	0(0)		22(21.8)	0(0)	
	3b	8(10.1)	10(29.4)		18(17.8)	0(0)	
	5	6(7.6)	0(0)		6(5.9)	0(0)	
	6a	18(22.8)	7(20.6)		19(18.8)	6(50)	
	6b	1(1.3)	17(50)		12(11.9)	6(50)	
Surgical resection	Absent	5(6.3)	3(8.8)	0.695	7(6.9)	1(8.3)	0.858
	Present	74(93.7)	31(91.2)		94(93.1)	11(91.7)	
Multifocality	Absent	70(88.6)	18(52.9)	<0.001	85(84.2)	3(25)	<0.001
	Present	9(11.4)	16(47.1)		16(15.8)	9(75)	
Tumor necrosis	Absent	48(60.8)	3(8.8)	<0.001	50(49.5)	1(8.3)	0.007
	Present	31(39.2)	31(91.2)		51(50.5)	11(91.7)	
Age at diagnosis		59.5±13.1	58.1±14.4	0.614	59.7±13.3	54.3±14.5	0.189
Ki-67 proliferation index		6(2-15)	25(15-40)	<0.001	8(3-20)	40(25-55)	<0.001

Loss of p16 expression was significantly associated with larger tumor size (p<0.001), EZH2 overexpression (p=0.001), increased mitotic activity (p<0.001), survival status (p<0.001), distant metastasis (p<0.001), higher AFIP risk category (p<0.001), multifocality (p<0.001), tumor necrosis (p<0.001), and higher Ki-67 proliferation index (p<0.001).

Similarly, EZH2 overexpression was significantly associated with increased mitotic activity (p<0.001), survival status (p=0.004), distant metastasis (p<0.001), higher AFIP risk category (p<0.001), multifocality (p<0.001), tumor necrosis (p=0.007), and higher Ki-67 proliferation index (p<0.001). No significant associations were observed between p16 or EZH2 expression and any of the following variables: age, sex, CD117 expression, DOG1 expression, histological subtype, or surgical treatment status (Table 2).

Comparison by survival status showed that deceased patients had significantly larger tumors (p=0.002), more frequent EZH2 overexpression (p=0.004), loss of p16 expression (p<0.001), and higher mitotic activity (p<0.001). In addition, distant metastasis (p<0.001), a high AFIP risk category (p<0.001), multifocality (p<0.001), tumor necrosis (p<0.001), and a high Ki-67 proliferation index (p<0.001) were significantly more common in deceased patients than in survivors. No significant differences were observed between the two groups with respect to age, sex, CD117 expression, DOG1 expression, histological subtype, or surgical treatment status (Table 3).

Table 3: Comparison of Clinicopathological Characteristics According to Survival Status in Patients with Gastrointestinal Stromal Tumors

		Survival status		p
		Alive(%)	Dead(%)	
Gender	Male	36(49.3)	24(60)	0.276
	Female	37(50.7)	16(40)	
Tumor size (cm)	≤2	9(12.3)	0(0)	0.002
	> 2 to ≤ 5	19(26)	3(7.5)	
	> 5 to ≤ 10	29(39.7)	18(45)	
	> 10	16(21.9)	19(47.5)	
CD117 expression	negative	5(6.8)	4(10)	0.718
	positive	68(93.2)	36(90)	
DOG1 expression	negative	2(2.7)	1(2.5)	0.940
	positive	71(97.3)	39(97.5)	
EZH2 expression	negative	70(95.9)	31(77.5)	0.004
	positive	3(4.1)	9(22.5)	
Loss of p16 expression	negative	62(84.9)	17(42.5)	<0.001
	positive	11(15.1)	23(57.5)	
Histological subtype	Spindle cell	65(89)	31(77.5)	0.248
	Epithelioid	5(6.8)	5(12.5)	
	Mixed	3(4.1)	4(10)	
Mitotic count (mitoses/5 mm2)	≤5	55(75.3)	9(22.5)	<0.001
	>5	18(24.7)	31(77.5)	
Metastatic status	None	58(79.5)	16(40)	<0.001
	Unifocal	8(11)	12(30)	
	Multifocal	7(9.6)	12(30)	
AFIP risk category	1	9(12.3)	0(0)	<0.001
	2	12(16.4)	3(7.5)	

		Survival status		p
		Alive(%)	Dead(%)	
	3a	21(28.8)	1(2.5)	
	3b	13(17.8)	5(12.5)	
	5	6(8.2)	0(0)	
	6a	9(12.3)	16(40)	
	6b	3(4.1)	15(37.5)	
Surgical resection	Absent	5(6.8)	3(7.5)	0.897
	Present	68(93.2)	37(92.5)	
Multifocality	Absent	66(90.4)	22(55)	<0.001
	Present	7(9.6)	18(45)	
Tumor necrosis	Absent	45(61.6)	6(15)	<0.001
	Present	28(38.4)	34(85)	
Age at diagnosis		58.4±12.5	60.3±15.1	0.476
Ki-67 proliferation index		5(3-10)	25(20-40)	<0.001

Kaplan–Meier survival analysis demonstrated significant differences in OS according to several clinicopathological variables (Figure 2). Patients with EZH2 overexpression had a median OS of 29.70 months (95% CI: 18.36–41.04), whereas EZH2-negative patients had a median OS of 77.74 months (95% CI: 68.32–87.16) (log-rank p=0.001). Likewise, patients with loss of p16 expression had a significantly shorter median OS than those with preserved p16 expression (42.12 months [95% CI: 26.91–57.33] vs. 88.21 months [95% CI: 78.93–97.49], log-rank p<0.001).

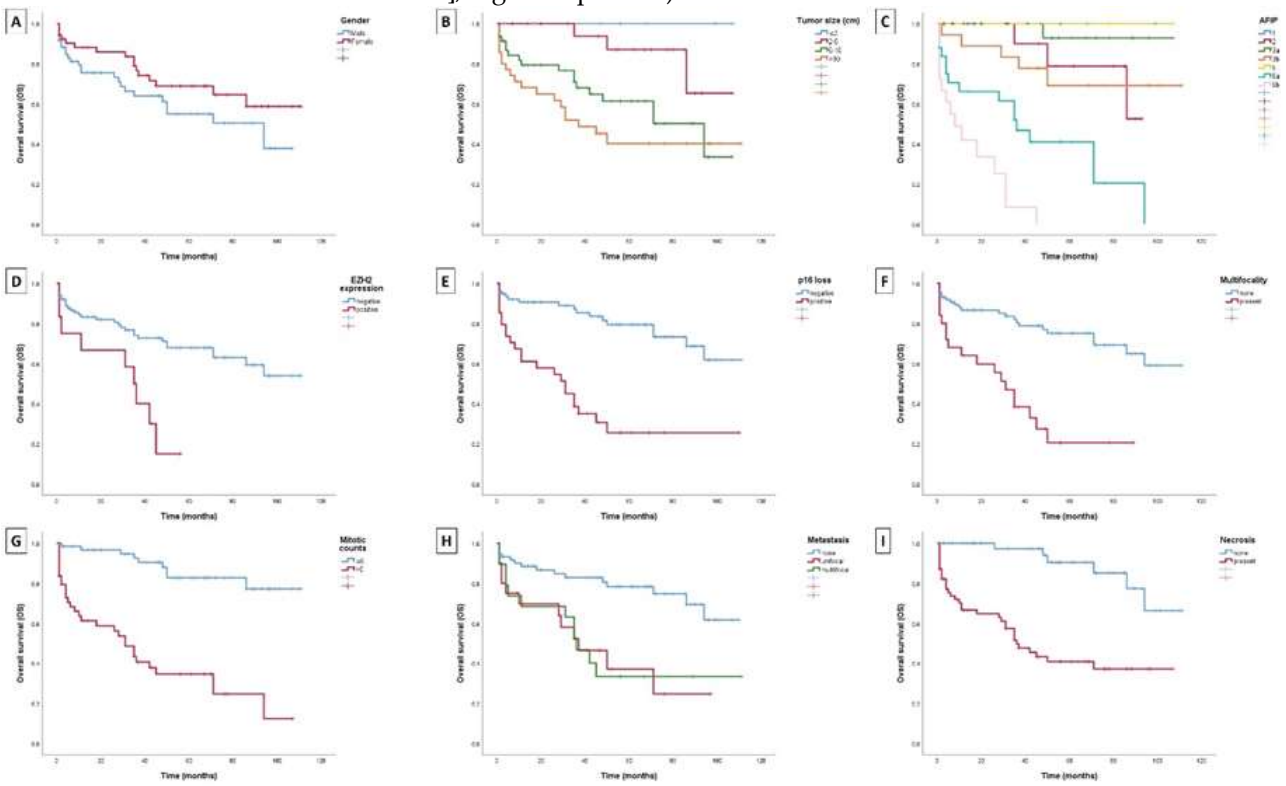

Figure 2. Kaplan-Meier survival analysis of overall survival (OS) according to A) Gender B) Tumor size (cm) C) AFIP risk category D) EZH2 expression E) Loss of p16 expression F) Multifocality G) Mitotic count (mitoses/5 mm2) H) Metastasis I) Tumor necrosis

Patients with a mitotic count >5 had a median OS of 42.16 months (95% CI: 29.90–54.43), whereas those with a mitotic count ≤5 had a median survival of 96.57 months (95% CI: 88.02–105.11) (log-rank p<0.001). Patients without metastasis had a median survival of 86.32 months (95% CI: 76.33–96.30), whereas patients with unifocal and multifocal metastases had median survival times of 51.70 months (95% CI: 31.10–72.29) and 45.98 months (95% CI: 28.61–63.34) respectively (log-rank p<0.001). OS also differed significantly among AFIP risk groups (log-rank p<0.001). Patients with multifocal tumors had a significantly shorter mean survival than those with solitary tumors (35.13 months [95% CI: 22.04–48.23] vs. 83.94 months [95% CI: 74.47–93.42], log-rank p<0.001). Likewise, patients with tumor necrosis had significantly shorter mean survival than those without necrosis (52.86 months [95% CI: 40.97–64.75] vs. 98.47 months [95% CI: 89.71–107.23], log-rank p<0.001).

In univariable Cox regression analysis, AFIP risk category (HR: 1.825, 95% CI: 1.488–2.237; p<0.001), EZH2 overexpression (HR: 3.246, 95% CI: 1.514–6.962; p=0.002), and loss of p16 expression (HR: 4.904, 95% CI: 2.566–9.374; p<0.001) were significantly associated with OS. Age and sex were not significantly associated with OS.

In the multivariable Cox regression analysis, AFIP risk category (HR: 1.661, 95% CI: 1.333–2.068; p<0.001) and loss of p16 expression (HR: 2.159, 95% CI: 1.035–4.506; p=0.040) remained independent predictors of OS. In contrast, EZH2 overexpression was not independently associated with OS after adjustment for other covariates (HR: 1.001, 95% CI: 0.409–2.447; p=0.999) (Table 4).

Table 4:Univariable and Multivariable Cox Regression Analysis of Factors Associated with Overall Survival in Patients with Gastrointestinal Stromal Tumors

	Univariable Cox Regression		**Multivariable Cox Regression**	
	HR (95% CI)	**p**	**HR (95% CI)**	**p**
Age at diagnosis	1.014(0.990-1.039)	0.269	1.009(0.981-1.037)	0.544
Gender (male)	1.605(0.850-3.030)	0.145	1.580(0.789-3.167)	0.197
AFIP risk category	1.825(1.488-2.237)	<0.001	1.661(1.333-2.068)	<0.001
EZH2 overexpression	3.246(1.514-6.962)	0.002	1.001(0.409-2.447)	0.999
Loss of p16 expression	4.904(2.566-9.374)	<0.001	2.159(1.035-4.506)	0.04

HR:hazard ratio; CI:confidence interval

4. Discussion

Gastrointestinal stromal tumors (GISTs) display remarkable biological heterogeneity, making accurate prediction of their clinical behavior challenging. Although current risk stratification systems primarily rely on tumor size, mitotic activity, and anatomical location, considerable differences in clinical outcomes are observed even among patients within the same risk category. Consequently, identifying molecular biomarkers that complement conventional clinicopathological parameters and more accurately reflect tumor biology has become increasingly important for improving prognostic assessment and identifying potential therapeutic targets.

In the present study, we evaluated the IHC expression of p16 and EZH2 in a retrospective cohort of 113 patients with GIST. Our findings demonstrate that loss of p16 expression and EZH2 overexpression are closely associated with adverse clinicopathological features. Moreover, p16 loss remained an independent prognostic factor in multivariable

analysis, whereas the prognostic effect of EZH2 appeared to be largely attributable to its close association with established high-risk pathological features.

4.1. EZH2 Overexpression

EZH2 overexpression was uncommon (10.6%) in our cohort but was clearly associated with an aggressive GIST phenotype. Rather than being distributed across the disease spectrum, EZH2 expression was predominantly observed in tumors with adverse pathological features and higher AFIP risk categories. This pattern suggests that EZH2 overexpression may be linked to biological progression and tumor aggressiveness rather than being a ubiquitous molecular event in GIST. Notably, all EZH2-positive tumors belonged to the highest AFIP risk categories (6A and 6B), while none were observed in the low- or intermediate-risk groups. This distribution strongly suggests that EZH2 overexpression is a characteristic of biologically aggressive GISTs rather than a common molecular alteration across all risk categories.

Although EZH2-positive tumors demonstrated markedly worse clinicopathological characteristics, EZH2 expression did not retain independent prognostic significance in the multivariable Cox regression analysis after adjustment for AFIP risk category and p16 expression. This finding suggests that the prognostic information provided by EZH2 substantially overlaps with that captured by established pathological risk factors, particularly AFIP classification and p16 loss. Therefore, EZH2 may function primarily as a marker of aggressive tumor biology rather than as an independent prognostic biomarker.

Studies investigating the role of EZH2 in GIST remain scarce. Miao et al. demonstrated that EZH2 promotes GIST progression by suppressing the Wnt4 signaling pathway through PAX8 promoter methylation, thereby providing mechanistic evidence for its oncogenic role.[28] Similarly, Ji et al. identified the SMYD2–EZH2–TET1 signaling axis as an important regulator of GIST progression and showed that EZH2 silencing induces cellular senescence.[29] Although these investigations were primarily based on experimental models, they provide strong biological support for the associations observed in our patient cohort. Our findings extend these experimental observations by demonstrating that EZH2 overexpression is closely associated with aggressive clinicopathological characteristics of clinical GIST specimens.

The relationship between EZH2 overexpression and adverse prognosis has also been extensively documented in several other malignancies, including breast, prostate, and lung carcinomas.[18,21,30] The present results are consistent with these observations and further support the concept that EZH2 contributes to tumor progression through conserved epigenetic mechanisms across different tumor types.

4.2. Loss of p16 Expression

Loss of p16 expression was observed in 34 of the 113 GISTs (30.1%). Although this frequency is slightly lower than the 40–70% range reported in previous studies,[14-17] considerable variability among published series is expected because of differences in IHC antibodies, scoring systems, and cutoff values. Indeed, this methodological heterogeneity has been highlighted in the meta-analysis by Zong et al., which included nine studies comprising 817 patients.[17]

In the present study, loss of p16 expression was consistently associated with adverse clinicopathological characteristics, including larger tumor size, increased mitotic activity, distant metastasis, tumor necrosis, multifocality, higher Ki-67 proliferation index, and poorer survival. More importantly, p16 loss remained an independent predictor of OS after adjustment for AFIP risk category and EZH2 expression, indicating that its prognostic value extends beyond conventional pathological risk factors.

The prognostic significance of p16 in GIST has been investigated for more than two decades, although the reported results have not always been consistent. Ricci et al.

demonstrated that loss of p16 expression, defined using a 20% IHC cutoff, was an independent prognostic factor associated with an increased risk of disease progression.[14] Likewise, Schneider-Stock et al. identified alterations in p16INK4a as independent predictors of outcome, particularly in benign and borderline GISTs.[25] Mitomi et al. further reported a significant association between loss of p16 expression and tumor progression in gastric GISTs,[31] whereas Haller et al. suggested that strong cytoplasmic p16 expression was independently associated with disease-free survival.[16] Collectively, these studies support the concept that disruption of the p16/CDKN2A pathway represents an important event in GIST progression.

Not all published studies, however, have reached the same conclusion. Huang et al., in a large cohort of 277 GISTs, observed only a borderline association between p16INK4A loss and patient survival,[26] whereas Schneider-Stock et al. demonstrated an independent prognostic effect in multivariable analysis.[25] These discrepancies are likely attributable to differences in study design, including the evaluation of protein expression versus combined genetic and epigenetic alterations, the use of different IHC scoring systems, and the variation in patient selection and follow-up duration.

More recent studies have also produced heterogeneous findings. Yakovtsova et al. reported that cytoplasmic p16INK4A expression correlated with Ki-67 proliferation index, VEGF, and MMP-9 expression and reflected a more aggressive tumor phenotype.[32] In contrast, Zaki et al. unexpectedly found that preserved p16 expression, rather than p16 loss, was associated with shorter disease-free survival and OS in a series of 65 patients.[33] These conflicting observations suggest that the biological role of the p16/CDKN2A pathway in GIST is likely more complex than a simple loss-of-function mechanism and may depend on tumor subtype, underlying molecular alterations, or methodological differences in IHC assessment.

Taken together, our findings strengthen the evidence supporting p16 loss as a clinically relevant prognostic biomarker in GIST. The persistence of its prognostic significance after multivariable adjustment suggests that assessment of p16 expression may provide additional prognostic information beyond currently established risk classification systems. Nevertheless, prospective multicenter studies using standardized IHC protocols and scoring criteria are needed before p16 can be incorporated into routine prognostic assessment.

4.3. The Epigenetic Relationship Between EZH2 Overexpression and Loss of p16 Expression

One notable finding of the present study was a significant association between EZH2 overexpression and loss of p16 expression. EZH2 overexpression was substantially more frequent in tumors showing p16 loss, suggesting that these alterations may be biologically interconnected. However, because our study was based on IHC assessment, this association should not be interpreted as evidence of a direct causal relationship.

EZH2 is the catalytic subunit of the Polycomb Repressive Complex 2 (PRC2) and mediates trimethylation of histone H3 at lysine 27 (H3K27me3), an epigenetic modification associated with transcriptional repression. Through this mechanism, EZH2 can suppress the expression of several tumor suppressor genes, including CDKN2A, which encodes the p16 protein. Experimental studies in other tumor types have provided support for this regulatory relationship. Bai et al. demonstrated that pharmacological inhibition of EZH2 restored p16 and p21 expression and induced cellular senescence in gastric cancer models, while Lu et al. reported increased p16 expression and reduced cellular proliferation following EZH2 inhibition in ovarian carcinoma models.[22,23]

Although the EZH2–CDKN2A axis has not been extensively investigated in GIST, our findings provide clinical evidence of an association between these two alterations in GIST specimens. The coexistence of EZH2 overexpression and p16 loss may therefore

reflect activation of an epigenetic program that contributes to tumor progression. Importantly, however, the present study cannot establish whether EZH2-mediated repression of CDKN2A is responsible for p16 loss in GIST. Alternative mechanisms, including genetic alterations, promoter methylation, or other regulatory pathways affecting CDKN2A expression, may also contribute to p16 loss.

The biological relevance of this association is further supported by the observation that EZH2 overexpression was predominantly detected in tumors with aggressive pathological characteristics. Taken together, these findings raise the possibility that EZH2 activation and disruption of the p16/CDKN2A pathway may represent interconnected components of GIST progression. Future studies incorporating CDKN2A promoter methylation analysis, H3K27me3 profiling, EZH2 target-gene assessment, and functional inhibition experiments are warranted to determine whether EZH2 directly regulates p16 expression in GIST and whether pharmacological targeting of this pathway has therapeutic potential.

4.4. Relationship with the AFIP Risk Classification

The distribution of p16 loss and EZH2 overexpression across AFIP risk categories further supports their association with aggressive tumor biology. Both alterations were associated with higher AFIP risk categories, although their distribution patterns differed. EZH2 overexpression was particularly strongly associated with high-risk disease, whereas p16 loss was also observed in intermediate-risk tumors and was not restricted to the highest-risk categories. This broader distribution of p16 loss may indicate that disruption of the p16/CDKN2A pathway can occur at an earlier stage of tumor progression.

The different distribution patterns of these two markers may also have prognostic implications. The persistence of p16 loss as an independent prognostic factor after adjustment for the AFIP risk category suggests that p16 assessment may provide prognostic information beyond conventional pathological risk stratification. In contrast, the loss of independent prognostic significance of EZH2 after multivariable adjustment is consistent with its close association with established high-risk pathological features.

These findings suggest that p16 IHC assessment may complement AFIP risk classification by providing additional biological information, particularly in patients with intermediate- and high-risk disease. However, larger multicenter studies are required to determine whether incorporation of p16 expression into existing risk stratification systems provides clinically meaningful improvement in prognostic accuracy.

4.5. Clinical Implications

The findings of the present study have potential clinical implications in two important respects. First, the independent prognostic significance of p16 loss suggests that this marker may complement existing clinicopathological risk stratification systems. Because IHC assessment of p16 is inexpensive, readily available, and easily incorporated into routine diagnostic practice, it may represent a practical adjunct for identifying patients at increased risk of disease progression, particularly among those classified as having intermediate- or high-risk disease according to the AFIP system.

Second, the observed association between EZH2 overexpression and loss of p16 expression highlights the potential biological relevance of the EZH2/PRC2 pathway in GIST. EZH2 represents an established therapeutic target in several malignancies, and selective EZH2 inhibitors have already entered clinical practice. Tazemetostat has demonstrated durable clinical responses in patients with SMARCB1 (INI1)-deficient epithelioid sarcoma, leading to its regulatory approval for this indication.[34] Although the therapeutic role of EZH2 inhibition in GIST has not yet been established, the observation in this study that EZH2 overexpression is restricted to biologically aggressive tumors suggests that this pathway merits further investigation, particularly in advanced or imatinib-resistant

disease. Consistent with this hypothesis, recent reviews have identified epigenetic therapy as a promising direction for future GIST research.[27]

Future experimental studies using GIST cell lines, patient-derived organoids, and animal models will be essential to determine whether pharmacological inhibition of EZH2 can reverse p16 suppression, reduce tumor proliferation, or enhance sensitivity to tyrosine kinase inhibitors.

5. Study Limitations

Our study has several limitations. First, the retrospective, single-center design may have introduced selection bias and may have limited the generalizability of the findings. Second, the relatively small number of EZH2-positive cases (n = 12) reduced the statistical power of subgroup analyses and may have limited the ability to detect associations with certain clinicopathological parameters, such as tumor size. Although EZH2 overexpression was significantly associated with shorter OS in Kaplan–Meier analysis, the limited number of EZH2-positive cases may have reduced the statistical power of the multivariable analysis and the ability to establish its independent prognostic significance. Third, the lack of a standardized IHC cutoff for EZH2 expression in GIST limits direct comparison with other studies. Finally, molecular analyses, including CDKN2A promoter methylation and H3K27me3 profiling, as well as functional studies of the EZH2–p16/CDKN2A axis, were not performed. Therefore, the observed association between EZH2 overexpression and p16 loss should be considered hypothesis-generating and should be confirmed in larger, prospective, multicenter studies incorporating molecular and functional analyses.

6. Conclusions

In conclusion, this study demonstrates that loss of p16 expression and overexpression of EZH2 are closely associated with aggressive clinicopathological features of GIST, including increased mitotic activity, metastasis, tumor necrosis, and higher AFIP risk categories. Among these biomarkers, loss of p16 emerged as an independent predictor of OS, whereas the prognostic significance of EZH2 appeared to reflect its close association with established high-risk pathological features. The significant correlation between EZH2 overexpression and p16 loss supports the hypothesis that dysregulation of the EZH2/PRC2–CDKN2A pathway contributes to GIST progression through epigenetic mechanisms. These findings suggest that p16 may serve as a useful adjunctive prognostic biomarker, while EZH2 represents a promising candidate for future translational and therapeutic research. Further prospective multicenter studies incorporating molecular validation and functional analyses are warranted to confirm these observations and clarify their potential clinical implications.

genAI: While preparing this manuscript, the authors used OpenAI ChatGPT and Pooltext to improve the manuscript's English-language usage and grammar. The authors reviewed and edited all AI-assisted content and accept full responsibility for the final manuscript.

Author Contributions: Project administration, conceptualization, methodology, validation, writing—original draft preparation, writing—review and editing, investigation, T.T., methodology, data curation, writing—review and editing, supervision, investigation, K.E.A., A.A.; data curation, resources, investigation writing—review and editing C.K.P., T.K., U.T; validation, software, visualization, formal analysis, methodology Y.K.A. All authors have read and agreed to the published version of the manuscript.

Funding: This research did not receive any specific grants from any public, commercial, or nonprofit funding organization.

Conflicts of Interest: The authors declare no conflicts of interest. The funders had no role in the study design; data collection, analysis, or interpretation; the writing of the manuscript; or the decision to publish the results.

Statement of Ethics: This study was approved by the Çukurova University Faculty of Medicine Non-Interventional Clinical Research Ethics Committee (Decision No. 69, July 10, 2026). Conducted per the Declaration of Helsinki.

Informed Consent Statement: Patient consent was waived due to the retrospective nature of the study. The research involved the analysis of existing electronic medical records obtained between 2016 and 2026; all data were accessed in anonymized form to ensure patient confidentiality.

Data Availability Statement: Data supporting the findings of this study are available from the corresponding author upon reasonable request. The data were not publicly available because of ethical and privacy restrictions protecting patient confidentiality.

Acknowledgements: None

References

1. WHO Classification of Tumours Editorial Board. Digestive system tumours. In WHO Classification of Tumours Series, 5th ed.; International Agency for Research on Cancer: Lyon, France, 2019; Vol. 1, pp. 1–435.
2. Joensuu H, Kindblom LG. Gastrointestinal stromal tumors–a review. Acta Orthop Scand Suppl. 2004;75(311):62-71. https://doi.org/10.1080/00016470410001708340
3. Miettinen M, Lasota J. Gastrointestinal stromal tumors: pathology and prognosis at different sites. Semin Diagn Pathol. 2006;23(2):70-83. doi: https://doi.org/10.1053/j.semdp.2006.09.001
4. Hirota S, Isozaki K, Moriyama Y, Hashimoto K, Nishida T, Ishiguro S, et al. Gain-of-function mutations of c-kit in human gastrointestinal stromal tumors. Science. 1998;279(5350):577-80. https://doi.org/10.1126/science.279.5350.577
5. Emile JF, Brahimi S, Coindre JM, Bringuier PP, Monges G, Samb P, et al. Frequencies of KIT and PDGFRA mutations in the MolecGIST prospective population-based study differ from those of advanced GISTs. Med Oncol. 2012;29(3):1765-72. doi: https://doi.org/10.1007/s12032-011-0074-y
6. Calabuig-Fariñas S, López-Guerrero JA, Llombart-Bosch A. The GIST paradigm: how to establish diagnostic and prognostic criteria. Arkhiv Patol. 2011;73(4):13-21.
7. Adil MT, Sagar J, Das P, Jain V. Gastrointestinal stromal tumours: a review on genetics, pathology, risk stratification, clinical characteristics, investigation, and treatment. EMJ Oncol. 2019;7(1):62-70.
8. Rossi S, Gasparotto D, Miceli R, Toffolatti L, Gallina G, Scaramel E, et al. KIT, PDGFRA, and BRAF mutational spectrum impacts on the natural history of imatinib-naive localized GIST: a population-based study. Am J Surg Pathol. 2015;39(7):922-30. https://doi.org/10.1097/PAS.0000000000000418
9. Fletcher CD, Berman JJ, Corless C, Gorstein F, Lasota J, Longley BJ, et al. Diagnosis of gastrointestinal stromal tumors: a consensus approach. Hum Pathol. 2002;33(5):459-65. https://doi.org/10.1053/hupa.2002.123545
10. Miettinen M, Lasota J. Gastrointestinal stromal tumors: review on morphology, molecular pathology, prognosis, and differential diagnosis. Arch Pathol Lab Med. 2006;130(10):1466-78. https://doi.org/10.5858/2006-130-1466-GSTROM
11. Joensuu H, Rutkowski P, Nishida T, Steigen SE, Brabec P, Plank L, et al. KIT and PDGFRA mutations and the risk of GI stromal tumor recurrence. J Clin Oncol. 2015;33(6):634-42. https://doi.org/10.1200/JCO.2014.57.4970
12. Demetri GD, von Mehren M, Blanke CD, Van den Abbeele AD, Eisenberg B, Roberts PJ, et al. Efficacy and safety of imatinib mesylate in advanced gastrointestinal stromal tumors. N Engl J Med. 2002;347(7):472-80. https://doi.org/10.1056/NEJMoa020461
13. Serrano M, Hannon GJ, Beach D. A new regulatory motif in cell-cycle control causing specific inhibition of cyclin D/CDK4. Nature. 1993;366(6456):704-7. https://doi.org/10.1038/366704a0
14. Ricci R, Arena V, Castri F, Martini M, Maggiano N, Murazio M, et al. Role of p16/INK4a in gastrointestinal stromal tumor progression. Am J Clin Pathol. 2004;122(1):35-43. https://doi.org/10.1309/MJ4X-N2M5-7HNC-8X5H
15. Haller F, Löbke C, Ruschhaupt M, Cameron S, Füzesi L, Sültmann H, et al. Loss of 9p leads to p16INK4A down-regulation and enables RB/E2F1-dependent cell cycle promotion in gastrointestinal stromal tumours (GISTs). J Pathol. 2008;215(3):253-62. https://doi.org/10.1002/path.2352

16. Haller F, Agaimy A, Cameron S, Beyer M, Gunawan B, Happel N, et al. Expression of p16INK4A in gastrointestinal stromal tumours (GISTs): two different forms exist that independently correlate with poor prognosis. Histopathology. 2010;56(3):305-18. https://doi.org/10.1111/j.1365-2559.2010.03478.x
17. Zong L, Chen P, Jiang J, Wang H, Wang L. Correlation between p16 expression and malignant risk of gastrointestinal stromal tumor: evidence from nine studies. Hepatogastroenterology. 2012;59(117):1458-1463. https://doi.org/10.5754/hge11473
18. Varambally S, Dhanasekaran SM, Zhou M, Barrette TR, Kumar-Sinha C, Sanda MG, et al. The polycomb group protein EZH2 is involved in progression of prostate cancer. Nature. 2002;419(6907):624-629. https://doi.org/10.1038/nature01075
19. Cao R, Wang L, Wang H, Xia L, Erdjument-Bromage H, Tempst P, et al. Role of histone H3 lysine 27 methylation in Polycomb-group silencing. Science. 2002;298(5595):1039-43. https://doi.org/10.1126/science.1076997
20. Simon JA, Kingston RE. Mechanisms of polycomb gene silencing: knowns and unknowns. Nat Rev Mol Cell Biol. 2009;10(10):697-708. https://doi.org/10.1038/nrm2763
21. Cao W, Ribeiro RO, Liu D, Saintigny P, Xia R, Xue Y, et al. EZH2 promotes malignant behaviors via cell cycle dysregulation and its mRNA level associates with prognosis of patient with non-small cell lung cancer. PLoS One. 2012;7(12):e52984. https://doi.org/10.1371/journal.pone.0052984
22. Bai J, Chen J, Ma M, Cai M, Xu F, Wang G, et al. Inhibiting enhancer of zeste homolog 2 promotes cellular senescence in gastric cancer cells SGC-7901 by activation of p21 and p16. DNA Cell Biol. 2014;33(6):337-44. https://doi.org/10.1089/dna.2014.2340
23. Lu F, Xu H, Wang Q, Li M, Meng J, Kuang Y. Inhibition of enhancer of zeste homolog 2 increases the expression of p16 and suppresses the proliferation and migration of ovarian carcinoma cells in vitro and in vivo. Oncol Lett. 2018;15(3):3233-39. https://doi.org/10.3892/ol.2017.7712
24. Jiang T, Wang Y, Zhou F, Gao G, Ren S, & Zhou C. Prognostic value of high EZH2 expression in patients with different types of cancer: a systematic review with meta-analysis. Oncotarget, 2015;7(4), 4584. https://doi.org/10.18632/oncotarget.6612
25. Schneider-Stock R, Boltze C, Lasota J, Miettinen M, Peters B, Pross M, Roessner A, Günther T. High prognostic value of p16INK4 alterations in gastrointestinal stromal tumors. J Clin Oncol. 2003;21(9):1688-97. https://doi.org/10.1200/JCO.2003.08.101
26. Huang HY, Huang WW, Lin CN, Eng HL, Li SH, Li CF, Lu D, Yu SC, Hsiung CY. Immunohistochemical expression of p16INK4A, Ki-67, and Mcm2 proteins in gastrointestinal stromal tumors: prognostic implications and correlations with risk stratification of NIH consensus criteria. Ann Surg Oncol. 2006;13(12):1633-44. https://doi.org/10.1245/s10434-006-9188-4
27. Sioulas AD, Vasilatou D, Pappa V, Dimitriadis G, Triantafyllou K. Epigenetics in gastrointestinal stromal tumors: clinical implications and potential therapeutic perspectives. Dig Dis Sci. 2013;58(11):3094-102. https://doi.org/10.1007/s10620-013-2785-8
28. Miao Z, Wu F, Wei H, Luo Z, Wu K, Zhang J. Enhancer of zeste homolog 2-mediated paired box 8 methylation promotes gastrointestinal stromal tumor progression through Wnt4 downregulation. Cancer Gene Ther. 2021;28(10):1162-74. https://doi.org/10.1038/s41417-020-00266-5
29. Ji Y, Xu X, Long C, Wang J, Ding L, Zheng Z, et al. SMYD2 aggravates gastrointestinal stromal tumor via upregulation of EZH2 and downregulation of TET1. Cell Death Discov. 2022;8(1):278. https://doi.org/10.1038/s41420-022-01038-w
30. Meseure D, Vacher S, Alsibai KD, Nicolas A, Chemlali W, Caly M, et al. Expression of ANRIL-polycomb complexes-CDKN2A/B/ARF genes in breast tumors: identification of a two-gene (EZH2/CBX7) signature with independent prognostic value. Mol Cancer Res. 2016;14(7):623-33. https://doi.org/10.1158/1541-7786.MCR-15-0418
31. Mitomi H, Fukui N, Kishimoto I, Tanabe S, Kikuchi S, Saito T, et al. Role for p16(INK4a) in progression of gastrointestinal stromal tumors of the stomach: alteration of p16(INK4a) network members. Hum Pathol. 2011;42(10):1505-13. https://doi.org/10.1016/j.humpath.2011.01.005
32. Yakovtsova II, Miroshnichenko YM, Chertenko TM. Immunohistochemical features of gastrointestinal stromal tumors and the role of expression of p16ink4A, Ki-67, VEGF and MMP-9 in their behavior. Patologìa. 2021;18(2):136-41. https://doi.org/10.14739/2310-1237.2021.2.233425
33. Zaki MM, Enan ET, Hany H. Immunohistochemical expression of p16, p53, BCL2, and cyclin D1 in gastrointestinal stromal tumors: correlation with clinicopathological parameters. Cureus. 2025;17(10):e93731. https://doi.org/10.7759/cureus.93731
34. Gounder M, Schöffski P, Jones RL, Agulnik M, Cote GM, Villalobos VM, et al. Tazemetostat in advanced epithelioid sarcoma with loss of INI1/SMARCB1: an international, open-label, phase 2 basket study. Lancet Oncol. 2020;21(11):1423-32. https://doi.org/10.1016/S1470-2045(20)30451-4