Original Article

Cukurova Anestezi ve Cerrahi Bilimler Dergisi

Short-Term Outcomes of Carpal Tunnel Release in Patients with CRPS-Like Symptoms

Kadir Çevik[1]*, *Elif Cimilli*[2], *Egemen Ayhan*[1]

[1] Department of Hand Surgery, Başakşehir Çam and Sakura City Hospital, Istanbul, Türkiye

[2] Occupational Therapy Department of Faculty of Health Sciences, Hacettepe University, Ankara, Türkiye

***Correspondence:** Kadir Çevik, drkadircevik@gmail.com

Cite as: Çevik K, Cimilli E, Ayhan E. Short-Term Outcomes of Carpal Tunnel Release in Patients with CRPS-Like Symptoms. J Cukurova Anesth Surg. 2026;9(3):920-925. doi:10.36516/jocass.1998489

Received: 19.07.2026, **Accepted:** 15.09.2026, **Published:** 30.09.2026, **CC BY-NC 4.0**

Abstract

Introduction: Some patients diagnosed with complex regional pain syndrome (CRPS) may have an underlying peripheral nerve trigger, including mechanical irritation of the median nerve within the carpal tunnel. This study evaluated the short-term outcomes of carpal tunnel release in adults with persistent CRPS-like symptoms and suspected irritative carpal tunnel syndrome. **Methods:** This retrospective case series included adult patients who underwent mini-open carpal tunnel release after failing at least three months of medical treatment and hand therapy. Patients were assessed preoperatively and six weeks postoperatively using the visual analog scale (VAS), Patient-Specific Functional Scale (PSFS), Disabilities of the Arm, Shoulder and Hand (DASH) questionnaire, grip strength, and tripod pinch strength. Preoperative and postoperative values were compared using the two-sided exact Wilcoxon signed-rank test. **Results:** There were eight patients with a mean age of 55.0 ± 13.2 years. The median VAS score decreased from 8.0 to 0.0, the median PSFS score increased from 2.9 to 8.1, and the median DASH score decreased from 64.5 to 16.5 at six weeks postoperatively ($p = 0.008$ for all comparisons). Median grip strength increased from 8.3 to 10.2 kg, and median tripod pinch strength increased from 2.9 to 3.7 kg. **Conclusions:** Carpal tunnel release was associated with significant short-term improvements in pain and patient-reported hand function in selected adults with persistent CRPS-like symptoms and suspected irritative carpal tunnel syndrome. Median nerve irritation should be considered as a potentially treatable peripheral contributor in patients who do not improve with conventional CRPS treatment. Larger prospective studies with longer follow-up are needed.

Keywords: complex regional pain syndrome; irritative carpal tunnel syndrome; carpal tunnel release; median nerve; neuropathic pain

1. Introduction

Complex regional pain syndrome (CRPS) is a chronic pain disorder characterized by pain disproportionate to the inciting event, together with sensory, vasomotor, sudomotor, motor, and trophic abnormalities[1]. It commonly develops after trauma or surgery[2-5]. Patients may present with allodynia, hyperalgesia, edema, skin color changes, and marked restriction of hand motion, including an inability to make a full fist[1-3,6-8]. Symptoms may worsen at night and cause significant sleep disturbance[2,6,8].

CRPS is classified as type 1 or type 2 according to the presence of an identifiable nerve injury[1,7,9-11]. Type 1, formerly termed reflex sympathetic dystrophy, is diagnosed in the absence of demonstrable nerve injury, whereas Type 2, previously known as causalgia, is associated with a confirmed peripheral nerve lesion. However, previous reports have suggested that some patients diagnosed with CRPS Type 1 may have an underlying peripheral nerve trigger, including mechanical irritation of the median nerve within the carpal tunnel[2,3,8,12-19]. This clinical presentation has been termed irritative carpal tunnel syndrome. In these cases, mechanical irritation of the median nerve within the carpal tunnel, rather than conventional nerve compression, may produce an amplified pain response resembling CRPS. Although surgery has traditionally been approached cautiously in patients with CRPS, symptom improvement after carpal tunnel release has been reported in selected patients[2,8,10,13,14,16,17].

We hypothesized that median nerve irritation at the carpal tunnel may contribute to symptoms in a subgroup of patients referred with CRPS and that carpal tunnel release may improve pain and hand function. The aim of this study was to evaluate the short-term clinical outcomes of carpal tunnel release in adults with persistent CRPS-like symptoms and suspected irritative carpal tunnel syndrome after unsuccessful conservative treatment.

Methods

This retrospective case series included adult patients who underwent carpal tunnel release between September 2019 and February 2022 after having previously been diagnosed and treated for CRPS. Ethical approval was obtained from the Ethics Committee of Ministry of Health, Health Sciences University, Dışkapı Yıldırım Beyazıt Training and Research Hospital (Approval No. 144/22, dated 15/08/2022). The data were analyzed anonymously. Written informed consent was obtained from all patients for surgery and the use of their anonymized clinical data.

Patients were referred for a second opinion because of persistent symptoms despite medical treatment and hand therapy. Clinical findings raising suspicion of irritative carpal tunnel syndrome included diffuse hand allodynia or hyperesthesia, nocturnal worsening of symptoms, and an inability to make a full fist. All patients reported a preceding traumatic event. Before presentation to our clinic, they had received treatment for CRPS for a mean of 4.7 months (range, 3–12 months).

The inclusion criteria were: (1) age ≥18 years; (2) a previous diagnosis of CRPS with persistent CRPS-like symptoms; (3) clinical suspicion of irritative carpal tunnel syndrome; (4) failure to improve after at least three months of medical treatment and hand therapy; and (5) availability of preoperative and six-week postoperative clinical data. The exclusion criteria were: (1) an alternative diagnosis that clearly explained the symptoms; (2) previous peripheral nerve surgery in the affected extremity; (3) incomplete clinical records; and (4) refusal to participate.

All procedures were performed by one of the surgeon authors using a mini-open carpal tunnel release under wide-awake local anesthesia with no tourniquet (WALANT). No macroscopic signs of median nerve compression, including hyperemia or increased vascularity, were observed intraoperatively. Patients were evaluated by the same hand therapist preoperatively and at six weeks postoperatively. The outcome measures included pain severity assessed using a 10-point Visual Analog Scale (VAS), upper-extremity disability assessed using the Disabilities of the Arm, Shoulder, and Hand (DASH) questionnaire, patient-specific functional limitation assessed using the Patient-Specific Functional Scale (PSFS), and grip and tripod pinch strength. The PSFS is a patient-reported outcome measure in which patients identify activities that they have difficulty performing and rate their ability to perform each activity before and after treatment[23]. Higher

PSFS scores indicate better functional ability. Grip strength was measured using a calibrated Jamar dynamometer with the patient seated, the shoulder adducted and in neutral rotation, the elbow flexed to 90°, and the forearm and wrist in a neutral position. Tripod pinch strength was measured using a calibrated pinch gauge. Three measurements were obtained for each strength assessment, and the mean value was used for analysis.

Statistical analyses were performed using IBM SPSS Statistics for Windows, version 27.0 (IBM Corp., Armonk, NY, USA). Continuous variables were summarized as mean ± standard deviation and median with interquartile range. Preoperative and postoperative VAS, PSFS, DASH, grip strength, and tripod pinch strength values were compared using the two-sided exact Wilcoxon signed-rank test because of the small sample size and paired study design. A p value of less than 0.05 was considered statistically significant.

Results

Ten patients underwent carpal tunnel release for suspected irritative carpal tunnel syndrome. Two patients did not attend the six-week postoperative assessment and were excluded from the analysis. The final study group consisted of eight patients, including five women and three men. The mean age was 55.0 ± 13.2 years (range, 34–71 years).

At six weeks postoperatively, the median VAS score decreased from 8 (IQR, 5–8.3) to 0 (IQR, 0–2; p = 0.008). The median PSFS score increased from 2.9 (IQR, 2.0–4.1) to 8.1 (IQR, 4.9–8.4; p = 0.008), and the median DASH score decreased from 64.5 (IQR, 49.3–83.5) to 16.5 (IQR, 13.5–27.0; p = 0.008) (Table 1). Median grip strength increased from 8.3 kg (IQR, 2.4–12) to 11.6 kg (IQR, 8.6–17.2; p = 0.008), and median tripod pinch strength increased from 2.9 kg (IQR, 1.6–3.3) to 3.7 kg (IQR, 2.2–3.8; p = 0.039).

Table 1. Patient characteristics and clinical outcomes before and 6 weeks after carpal tunnel release.

Patient	Age (years)	Date of Surgery	Preop VAS	Postop VAS	Preop PSFS	Postop PSFS	Preop DASH	Postop DASH	Preop Grip (kg)	Postop Grip (kg)	Preop Tripod Pinch (kg)	Postop Tripod Pinch (kg)
1	66	Sep 2019	5	0	3.9	8.1	61	18	20.7	32.3	3.2	3.9
2	65	Nov 2019	8	0	3.3	8.3	68	20	18	22.7	2.5	2.3
3	34	Dec 2019	8	5	0.3	5	88	15	0	9.3	0.3	1.4
4	42	Feb 2020	4	0	7.7	8	20	12	10	11	3.9	4
5	60	Aug 2020	9	5	2.5	4.6	89	63	3.2	5.5	3.3	3.8
6	57	Sep 2020	5	0	4.5	8.5	50	14	10	15.3	3.4	3.6
7	71	Mar 2021	10	1	1	4.7	82	48	0	6.5	0	2
8	45	Jan 2022	8	0	2.3	9.2	47	3.3	6.5	12.1	2	3.8

Preop: Preoperative, Postop: Postoperative, VAS: Visual Analog Scale, DASH: Disabilities of the Arm, Shoulder, and Hand questionnaire, PSFS: Patient-Specific Functional Scale

Discussion

In this series, carpal tunnel release was associated with significant short-term improvements in pain and patient-reported hand function in adults previously diagnosed with CRPS. At six weeks, the median VAS and DASH scores had decreased, while the

median PSFS score had increased. Grip and tripod pinch strength also increased numerically, although these changes were not statistically significant.

Our findings are consistent with previous reports suggesting that median nerve irritation may contribute to CRPS-like symptoms in selected patients. In a retrospective review of 225 patients with a diagnosis of CRPS of the hand, del Piñal identified irritative carpal tunnel syndrome in 90 patients and reported a mean reduction of 7.5 points in pain scores after treatment[3]. In another series, isolated median nerve release was associated with complete symptom resolution in 79% of patients and discontinuation of pain medication[12]. Lavigogne et al. also reported improvement in pain, swelling, and stiffness after treatment directed at the carpal tunnel in patients with CRPS-like symptoms[8]. The marked reduction in pain observed in our patients is consistent with the possibility that median nerve irritation may contribute to persistent CRPS-like presentations in selected patients.

The possible association between peripheral nerve entrapment and CRPS-like symptoms has also been described in earlier studies. Stein reported pain relief and recovery of active motion after median nerve decompression in patients diagnosed with Sudeck syndrome[20]. Grundberg and Reagan identified coexisting carpal tunnel syndrome in patients with refractory reflex sympathetic dystrophy and reported improvement after decompression[17]. Other authors have similarly described peripheral mononeuropathies or nerve entrapment in patients initially diagnosed with CRPS and have reported improvement after surgical release[13,14,18,19]. These studies suggest that a treatable peripheral nerve disorder should be considered before symptoms are attributed solely to CRPS.

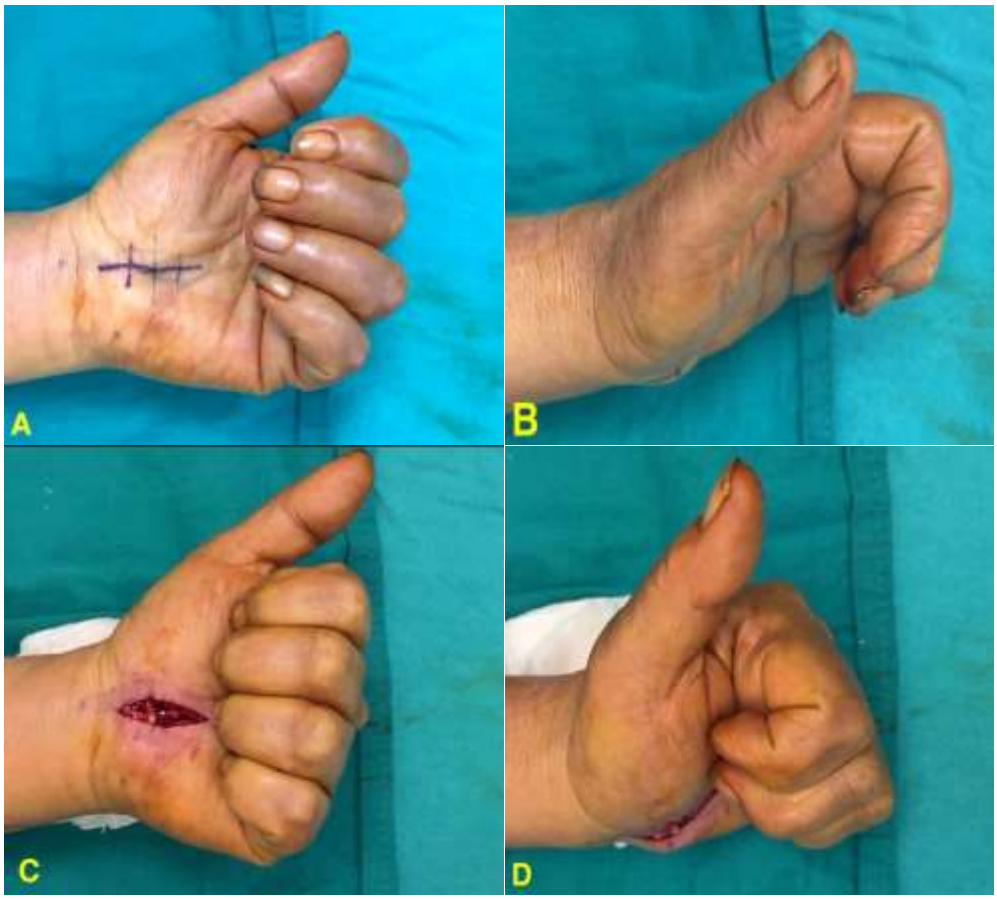

Figure 1. Assessment of active finger flexion under WALANT. *(A, B) Preoperative views demonstrating inability to make a full fist. (C, D) Intraoperative views obtained immediately after release of the transverse carpal ligament and before skin closure, demonstrating restoration of full active fist formation.*

The patients in our series presented with a clinical pattern that differed from classic carpal tunnel syndrome. Diffuse allodynia, nocturnal worsening of pain, sleep disturbance, and inability to make a full fist were more prominent than numbness confined to the median nerve distribution. In patients with severe hypersensitivity, conventional provocative tests such as Tinel's sign and Phalen's test may be difficult to interpret[6,12]. Pain during passive finger motion and limited active flexion have been proposed as additional clinical findings that may raise suspicion of median nerve irritation within the carpal tunnel[6,12]. Recognition of this pattern may help identify patients who require further evaluation for a peripheral nerve trigger.

Median grip and tripod pinch strength increased after surgery, but the differences were not statistically significant. This may reflect the small sample size and the short postoperative assessment interval. At six weeks, palmar tenderness following carpal tunnel release may still limit maximal effort during strength testing. In addition, prolonged painful disuse before surgery may require a longer period of rehabilitation before measurable recovery of strength occurs. However, longer follow-up would be required to determine whether strength continues to improve.

The use of WALANT allowed carpal tunnel release without tourniquet-related discomfort and permitted active finger motion to be assessed during the procedure. Patients could be asked to make a full fist after release of the transverse carpal ligament (Figure 1). However, the present study was not designed to determine whether the use of WALANT influenced postoperative outcomes.

This study has several limitations. First, its retrospective design and lack of a control group prevent conclusions regarding causality or comparison with continued conservative treatment. Second, only eight patients were included in the final analysis, and two patients were lost to the six-week follow-up. Third, postoperative outcomes were assessed at six weeks, and long-term symptom recurrence or continued functional recovery could not be evaluated. In addition, the diagnosis of suspected irritative carpal tunnel syndrome was based on clinical findings, and there is currently no universally accepted diagnostic test for this condition. Prospective studies with larger cohorts, standardized diagnostic criteria, control groups, and longer follow-up are needed.

In conclusion, in selected adults with persistent CRPS-like symptoms after upper-extremity trauma, carpal tunnel release was associated with significant short-term improvements in pain and patient-reported hand function. These findings suggest that median nerve irritation at the carpal tunnel should be considered as a potentially treatable peripheral contributor in patients who do not improve with conventional CRPS treatment. Larger prospective studies with longer follow-up are required to confirm these findings and define appropriate patient-selection criteria.

Author Contributions: Concept – Egemen Ayhan, Kadir Çevik; Design – Egemen Ayhan, Kadir Çevik; Supervision – Egemen Ayhan; Data Collection – Elif Cimilli; Literature Search – Egemen Ayhan, Kadir Çevik; Writing Manuscript – Egemen Ayhan, Kadir Çevik.

Conflict of Interest: The authors declare no conflict of interest in relation to this study.

Funding: This study was not supported by any sponsor or funder.

Ethical Approval: This study was approved by the Ministry of Health, Health Sciences University, Dışkapı Yıldırım Beyazıt Training and Research Hospital Ethics Committee on 15/08/2022 (Approval No: 144/22).

References

1. Shin SE, Haffner ZK, Chang BL, Kleiber GM. A Pilot Investigation into Targeted Muscle Reinnervation for Complex Regional Pain Syndrome, Type II. Plast Reconstr Surg Glob Open. 2022;10(12):e4718.
2. Del Piñal F. Outcomes of Carpal Tunnel Release in Complex Regional Pain Syndrome/Reflex Sympathetic Dystrophy/Sudeck Disease Patients. Plast Reconstr Surg. 2022;150(1):93-101.
3. Del Piñal F. Diagnosis and Outcomes of 225 Consecutive Cases of Complex Regional Pain Syndrome of the Hand. Plast Reconstr Surg. 2023;152(4):807-16.
4. van Eijs F, Stanton-Hicks M, Van Zundert J, Faber CG, Lubenow TR, Mekhail N, et al. Evidence-based interventional pain medicine according to clinical diagnoses. 16. Complex regional pain syndrome. Pain Pract. 2011;11(1):70-87.
5. Schwartzman RJ, Alexander GM, Grothusen JR. The use of ketamine in complex regional pain syndrome: possible mechanisms. Expert Rev Neurother. 2011;11(5):719-34.
6. Piñal FD. Hand Allodynia, Lack of Finger Flexion, and the Need for Carpal Tunnel Release. J Hand Surg Am. 2023;48(4):370-6.
7. Mills M, Howell CM. Complex regional pain syndrome. Jaapa. 2023;36(8):1-5.
8. Lavigogne C, Cromheecke M, De Keyzer PB, Coeman P, Goubau J. Carpal tunnel-targeted treatment in patients with CRPS-like symptoms: a retrospective cohort study of irritative carpal tunnel syndrome. Hand Surg Rehabil. 2026:102715.
9. Cutts S, Gangoo S, Srinivasan SH, Modi N, Pasapula C, Power D. Complex regional pain syndrome: an evolving perspective. Postgrad Med J. 2021;97(1146):250-5.
10. Chappell AG, Kalainov DM, Samworth A, Yuksel SS, Rangwani S, Nader A. Permanent Peripheral Nerve Stimulator for Complex Regional Pain Syndrome of the Forearm and Hand. Plast Reconstr Surg Glob Open. 2024;12(5):e5764.
11. Shim H, Rose J, Halle S, Shekane P. Complex regional pain syndrome: a narrative review for the practising clinician. Br J Anaesth. 2019;123(2):e424-e33.
12. Del Piñal F. Outcomes of Median Nerve Release in Complex Regional Pain Syndrome Type 1 of the Hand: A Prospective Case Series. J Hand Surg Am. 2025;50(2):130-7.
13. Placzek JD, Boyer MI, Gelberman RH, Sopp B, Goldfarb CA. Nerve decompression for complex regional pain syndrome type II following upper extremity surgery. J Hand Surg Am. 2005;30(1):69-74.
14. Koh SM, Moate F, Grinsell D. Co-existing carpal tunnel syndrome in complex regional pain syndrome after hand trauma. J Hand Surg Eur Vol. 2010;35(3):228-31.
15. Dellon AL, Andonian E, Rosson GD. CRPS of the upper or lower extremity: surgical treatment outcomes. J Brachial Plex Peripher Nerve Inj. 2009;4:1.
16. Dellon AL. Surgical Treatment of Upper Extremity Pain. Hand Clin. 2016;32(1):71-80.
17. Grundberg AB, Reagan DS. Compression syndromes in reflex sympathetic dystrophy. J Hand Surg Am. 1991;16(4):731-6.
18. Monsivais JJ, Baker J, Monsivais D. The association of peripheral nerve compression and reflex sympathetic dystrophy. J Hand Surg Br. 1993;18(3):337-8.
19. Thimineur MA, Saberski L. Complex regional pain syndrome type I (RSD) or peripheral mononeuropathy? A discussion of three cases. Clin J Pain. 1996;12(2):145-50.
20. Stein AH, Jr. The relation of median nerve compression to Sudeck's syndrome. Surg Gynecol Obstet. 1962;115:713-20.