Original Article

Cukurova Anestezi ve Cerrahi Bilimler Dergisi

Impact of Arthroscopes in the Diagnosis of the RAMP Lesion: 30° or 70° Arthroscope?

Bahattin Kemah[*1], *Emre Koraman*[2], *Mehmet Akif Cacan*[3], *Şafak Sayar*[4], *Barış Gülenç*[5], *Sercan Yalçın*[6], *Mehmet Emin Erdil*[7]

[1] Department of Orthopaedics and Traumatology, University of Health Science Umraniye Training and Research Hospital, Istanbul, Türkiye
[2] Department of Orthopaedics and Traumatology, Pendik Bolge Hospital, Istanbul, Türkiye
[3] Department of Orthopaedics and Traumatology, Medipol University, Istanbul, Türkiye
[4] Department of Orthopaedics and Traumatology, Biruni University, Istanbul, Türkiye
[5] Private Orthopaedics and Traumatology Clinic, Sweden
[6] Cleveland Clinic, Department of Orthopaedics and Traumatology, Cleveland, Ohio, United States
[7] Department of Orthopaedics and Traumatology, Maslak Acıbadem Hospital, Istanbul, Türkiye
***Correspondence:** Bahattin Kemah, MD; bahattinkemah.md@gmail.com
Cite as: Kemah B, Koraman E, Cacan MA, Sayar Ş, Gülenç B, Yalçın S, Erdil ME. Impact of Arthroscopes in the Diagnosis of the RAMP Lesion: 30° or 70° Arthroscope? J Cukurova Anesth Surg. 2026;9(3):807-816. doi: 10.36516/jocass.1961982
Received: 03.06.2026**, Accepted:** 17.09.2026**, Published:** 30.09.2026**,** **CC-BY-NC-4.0**

Abstract

Aim: This study compared the diagnostic accuracy of 30° and 70° arthroscopes used through standard anterior portals for detecting complete and partial RAMP lesions of the medial meniscus during anterior cruciate ligament (ACL) reconstruction. **Materials and Methods:** This prospective diagnostic accuracy study included 114 patients undergoing primary ACL reconstruction between August 2018 and August 2024, all with MRI findings suggestive of a RAMP lesion. Two senior surgeons (>20 years' experience) and two junior surgeons (<5 years' experience) independently evaluated the posteromedial compartment through the anterolateral portal using both arthroscopes in randomized order. Posteromedial portal inspection with probing served as the reference standard. Lesions were classified intraoperatively as complete or partial. Diagnostic accuracy, sensitivity, and interobserver agreement were calculated, and the effects of arthroscope angle, surgeon experience, and lesion subtype were analyzed using mixed-effects logistic regression. **Results:** Among 114 patients (mean age 26.8 ± 4.9 years; range, 18–35), 107 RAMP lesions (79 complete, 28 partial) were confirmed. For senior surgeons, sensitivities were 72.9% and 69.2% with 30°, and 96.3% and 92.5% with 70° ($p < 0.001$). Junior surgeons achieved 57.9% and 53.3% with 30°, and 73.8% and 69.2% with 70° ($p < 0.001$). Mixed-effects analysis showed independent effects of angle (OR = 4.9, $p < 0.001$) and experience (OR = 2.3, $p = 0.01$), with a significant Angle × Type interaction ($p = 0.04$). **Conclusion:** Although arthroscopy remains the gold standard for diagnosing RAMP lesions, using only a 30° arthroscope through the anterolateral portal may cause underdiagnosis, particularly of partial tears. Incorporating a 70° arthroscope enhances visualization and diagnostic accuracy regardless of surgeon experience.

Keywords: Anterior Cruciate Ligament Injuries; Arthroscopy; Knee Injuries; Sensitivity and Specificity; Tibial Meniscus Injuries

1. Introduction

The RAMP lesion is defined as a peripheral longitudinal tear of the posterior horn of the medial meniscus associated with an anterior cruciate ligament (ACL) rupture[1]. When viewed from the intercondylar notch, the posteromedial (PM) compartment resembles a ramp and corresponds to the peripheral attachment of the posteromedial horn of the medial meniscus and the meniscotibial ligament[1,2].

The role of the posterior horn of the medial meniscus in preventing the anterior translation of the tibia in the presence of an ACL rupture is well established. Therefore, its repair is crucial[3]. Controlled laboratory studies have demonstrated that anterior translation of the tibia and rotational instability in an ACL-deficient knee increase when a RAMP lesion is created at the posteromedial meniscocapsular junction[4,5].

Various studies have reported that the RAMP lesion is present in 9.3% to 16.9% of ACL ruptures[6–8]. Moreover, the incidence appears to rise in untreated chronic ACL ruptures, particularly those older than 24 months[7–9]. The diagnosis of the lesion is often challenging, and magnetic resonance imaging (MRI) is typically the first-line diagnostic tool. However, its reported sensitivity ranges between 48% and 77%[9–11]. Nonetheless, previous studies have indicated that arthroscopy is the gold standard for diagnosis, while MRI serves only as an adjunctive tool in clinical practice[12].

The objective of this study was to evaluate the diagnostic accuracy of different arthroscopes used through standard arthroscopic portals for the RAMP lesion, and it was hypothesized that a significant difference would be observed between 30° and 70° arthroscopes in diagnosing the RAMP lesion.

2. Materials and Methods

This prospective diagnostic accuracy study was performed in line with the principles of the Declaration of Helsinki and approved by the Institutional Ethics Committee of Istanbul Medeniyet University Göztepe Training and Research Hospital (Date: 15.08.2018, Approval No: 2018/0427). Written informed consent was obtained from all participants. The study was conducted between August 2018 and August 2024. The methodology followed the STARD (Standards for Reporting of Diagnostic Accuracy Studies) guidelines.

2.1. Patient Selection

Patients presenting with acute or chronic knee injuries were screened as potential participants.

Inclusion criteria: (1) age > 18 years, (2) ACL rupture confirmed by physical examination and MRI, (3) MRI findings suggestive of a RAMP lesion, (4) indication for primary ACL reconstruction, and (5) willingness to participate in the study.

Exclusion criteria: previous periarticular osteotomy, revision ACL reconstruction, ACL rupture secondary to knee dislocation, concurrent multi-ligament reconstruction, inflammatory joint disease, or incomplete preoperative imaging/records.

2.2. Radiological Evaluation

Preoperative MRI scans (MR360 Optima, GE Healthcare, Chicago, IL, USA) were obtained using a 1.5 T magnet and a standard extremity coil. Imaging sequences included sagittal T1-weighted and sagittal, axial, and coronal proton-density fat-suppressed or T2-weighted fat-suppressed images (FOV = 18.0 cm; interslice spacing = 1 mm; slice thickness = 2 mm).

Two musculoskeletal radiologists, blinded to arthroscopic findings, independently reviewed the MRIs. RAMP lesion suspicion was based on any of the following: 1- Fluid signal separating the posterior horn of the medial meniscus from the posteromedial

capsule. 2- Longitudinal tear in the peripheral posterior horn. 3- Focal discontinuity or step-like deformity at the posterior edge extending to the capsule. 4- Soft-tissue edema between the meniscus and medial collateral ligament. 5- Posteromedial tibial bone contusion with anterior translation of the medial tibial plateau relative to the femoral condyle[13]. Discrepancies were resolved by consensus.

2.3. Arthroscopic Procedure and Randomization

All procedures were performed under spinal anesthesia with the patient in a supine position and the operative leg supported in a leg holder to allow free motion. A tourniquet was used. Standard anterolateral (AL) and anteromedial (AM) portals were established for diagnostic arthroscopy.

The PM portal was not created until the completion of the initial AL-portal evaluations to prevent verification bias.

A computer-generated randomization sequence (sealed opaque envelopes) determined whether the 30° or 70° arthroscope was used first during the AL-portal inspection. The alternate scope was then used immediately afterward through the same portal. The order of arthroscope usage was balanced across patients to minimize sequence effects.

2.4. Arthroscopic Evaluation Protocol

Diagnostic evaluation was performed sequentially by two senior orthopaedic surgeons (each > 20 years' experience) and two junior surgeons (each < 5 years' experience).

Each surgeon independently inspected the posteromedial recess via the AL portal using both arthroscopes in randomized order, recording the presence or absence of a RAMP lesion and a 0-100 confidence score on standardized forms (where 0 indicated definite absence and 100 indicated definite presence of a RAMP lesion). No other surgeon was present during individual evaluations to avoid inter-observer influence (Figure 1, Figure 2).

Following all AL-portal assessments, one senior surgeon created the PM portal using an 18-gauge spinal needle placed 2.5 cm distal and 2.5 cm posterior to the medial femoral epicondyle. After confirming intra-articular position, the PM portal was established and the compartment examined sequentially with 30° and 70° arthroscopes.



Figure 1. Image of the RAMP lesion detected during examination with a 30° arthroscope through the anterolateral portal. *(PM-Cap: Posteromedial capsule, MTP: Medial tibial plateau, PHMM: Posterior horn of medial meniscus, MFC: Medial femoral condyle)*

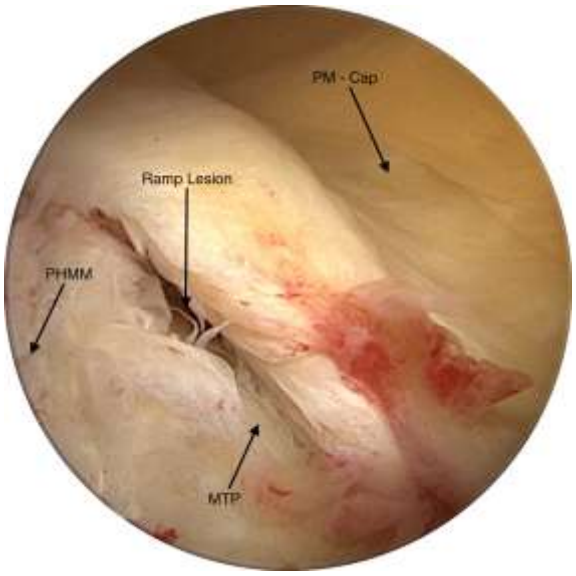

Figure 2. Image of the RAMP lesion detected during examination with a 70° arthroscope through the anterolateral portal. *(PM-Cap: Posteromedial capsule, MTP: Medial tibial plateau, PHMM: Posterior horn of medial meniscus)*

2.5. Definition of RAMP Lesions and Subclassification

A RAMP lesion was defined as meniscocapsular separation or a peripheral longitudinal tear at the posterior horn of the medial meniscus confirmed by direct visualization and probing through the PM portal.

Lesions were subclassified a priori as: Complete RAMP – distinct meniscocapsular separation with clear probe displacement ("door-sign"). Partial RAMP – limited peripheral separation or capsular laxity with < 5 mm probe displacement.

For the primary analysis, complete and partial lesions were pooled as "any ramp (positive)". Pre-specified secondary analyses compared diagnostic accuracy between complete and partial lesions separately.

2.6. Data Analysis

All statistical analyses were performed using NCSS 2007 (Statistical Software, Utah, USA).

Continuous variables were presented as mean ± standard deviation and categorical variables as frequencies and percentages. The diagnostic accuracy (sensitivity, specificity, positive predictive value, negative predictive value) of the 30° and 70° arthroscopes for RAMP lesion detection from the AL portal was calculated using PM-portal findings as the reference standard.

Paired proportions were compared using McNemar's test, and $p < 0.05$ was considered statistically significant. Interobserver reliability was evaluated using Cohen's kappa for binary outcomes and intraclass correlation coefficients (ICC[2,1]) for continuous confidence scores. Agreement strength was classified as: excellent > 0.80, very good 0.70-0.80, good 0.60-0.70, fair 0.40-0.60, poor < 0.40. To assess the impact of surgical experience and lesion subtype, a mixed-effects logistic regression model (random intercepts for patient and surgeon) included the fixed effects Angle (70° vs 30°), Experience (senior vs junior), Lesion Type (complete vs partial), and their interaction terms (Angle×Experience and Angle×Type).

A priori sample-size estimation using G*Power 3.1 ($\alpha = 0.05$, $1-\beta = 0.80$, expected discordance = 0.20, McNemar test) determined that a minimum of 98 patients would provide adequate statistical power.

3. Results

3.1. Patient Characteristics

A total of 133 patients were assessed for eligibility between August 2018 and August 2024.

Ten patients were excluded because preoperative imaging did not demonstrate sufficient findings suggestive of a RAMP lesion, four due to knee dislocation, four scheduled for revision ACL reconstruction, and one who declined participation. Consequently, 114 patients were included in the final analysis.

The mean age was 26.8 ± 4.9 years (range, 18-35), and the cohort consisted of 78 men (68.4%) and 36 women (31.6%).

Posteromedial portal reference inspection confirmed 107 RAMP lesions (93.9%), comprising 79 complete (73.8%) and 28 partial (26.2%) lesions.

3.2. Diagnostic Performance of Senior Surgeons (Table 1)

Using the 30° arthroscope, the first and second senior surgeons identified 78 and 74 RAMP lesions, respectively, whereas with the 70° arthroscope, they identified 103 and 99 lesions. Sensitivities were 72.9% and 69.2% for 30°, and 96.3% and 92.5% for 70°. The improvement with the 70° arthroscope was statistically significant ($p < 0.001$), while no significant difference existed between the two senior observers ($p = 0.27$). Specificities were 100% for both scopes.

Sub-analysis by lesion type: Complete RAMP lesions – sensitivity = 75.9% (30°) vs 97.5% (70°), $p < 0.001$. Partial RAMP lesions – sensitivity = 64.3% (30°) vs 92.9% (70°), $p = 0.004$.

Table 1. Diagnostic Performance of Senior Surgeons

Parameter	Senior 1 (30°)	Senior 1 (70°)	Senior 2 (30°)	Senior 2 (70°) / p
All RAMP lesions (n = 107)				
Detected, n	78	103	74	99 / <0.001
Sensitivity (%)	72.9	96.3	69.2	92.5
Specificity (%)	100	100	100	100
Sub-analysis by lesion type				
Complete RAMP (n = 79) – Sensitivity (%)	75.9	97.5	74.7	93.7 / <0.001
Partial RAMP (n = 28) – Sensitivity (%)	64.3	92.9	53.6	89.3 / 0.004

3.3. Diagnostic Performance of Junior Surgeons (Table 2)

Using the 30° arthroscope, the first junior surgeon detected 62 RAMP lesions and the second 57. With the 70° arthroscope, they detected 79 and 74, respectively. Corresponding sensitivities were 57.9% / 53.3% for 30° and 73.8% / 69.2% for 70°. Both junior surgeons demonstrated significantly improved detection with 70° optics ($p < 0.001$ and $p < 0.001$). Specificities were 100% for all comparisons.

Sub-analysis by lesion type: Complete lesions – sensitivity = 62.0% (30°) vs 80.8% (70°), $p < 0.001$. Partial RAMP lesions – sensitivity = 46.4% (30°) vs 64.3% (70°), $p = 0.01$.

Table 2. Diagnostic Performance of Junior Surgeons

Parameter	Junior 1 (30°)	Junior 1 (70°)	Junior 2 (30°)	Junior 2 (70°) / p
All RAMP lesions (n = 107)				
Detected, n	62	79	57	74 / <0.001 each
Sensitivity (%)	57.9	73.8	53.3	69.2
Specificity (%)	100	100	100	100
Sub-analysis by lesion type				
Complete RAMP (n = 79) – Sensitivity (%)	62.0	80.8	59.5	72.2 / 0.002
Partial RAMP (n = 28) – Sensitivity (%)	46.4	64.3	35.7	60.7 / 0.01

3.4. Effect of Surgical Experience (Table 3)

Across both optic angles, senior surgeons achieved higher diagnostic accuracy than juniors.

For 30°, sensitivity was 71% (seniors) versus 56% (juniors) (Δ = 15%, p = 0.02); for 70°, sensitivity was 94% (seniors) versus 71% (juniors) (Δ = 23%, p < 0.001).

In the mixed-effects logistic regression model (random intercepts for patient and surgeon): Angle (70° vs 30°) – Odds Ratio (OR) = 4.9 (95% Confidence Interval (CI) 2.1-11.5), p < 0.001. Experience (senior vs junior) – OR = 2.3 (95% CI 1.2-4.4), p = 0.01. Lesion type (complete vs partial) – OR = 1.8 (95% CI 1.0-3.3), p = 0.04. Angle × Experience interaction – p = 0.18 (not significant). Angle × Type interaction – p = 0.04, indicating a greater relative benefit of the 70° arthroscope for partial lesions.

Table 3. Effect of Surgical Experience on Diagnostic Accuracy

Variable	Odds Ratio	95% Confidence Interval	p Value	Interpretation
Angle (70° vs 30°)	4.9	2.1 – 11.5	<0.001	70° significantly increases detection accuracy
Experience (Senior vs Junior)	2.3	1.2 – 4.4	0.01	Senior surgeons show higher diagnostic accuracy
Lesion Type (Complete vs Partial)	1.8	1.0 – 3.3	0.04	Complete lesions more easily detected
Angle × Experience	—	—	0.18	Not significant
Angle × Type	—	—	0.04	Greater benefit of 70° optic for partial lesions

CI: confidence interval; OR: odds ratio. Results derived from a mixed-effects logistic regression model with random intercepts for patient and surgeon. p < 0.05 was considered statistically significant.

3.5. Interobserver Agreement

Among senior surgeons, interobserver agreement was excellent with κ = 0.87 (30°) and κ = 0.91 (70°). Among juniors, agreement was good to very good (κ = 0.74 (30°) and κ = 0.80 (70°)). Cross-agreement between senior and junior observers was κ = 0.70 (30°) and κ = 0.79 (70°). For continuous confidence scores, ICC(2,1) = 0.93 (95% CI 0.88-0.96), confirming excellent reproducibility.

4. Discussion

The primary finding of this study is that the 70° arthroscope provides significantly superior diagnostic accuracy compared with the 30° arthroscope for detecting RAMP lesions when standard anterolateral and anteromedial portals are used. This advantage was evident across both senior and junior surgeons and remained statistically significant after adjusting for surgical experience and lesion type. Although complete RAMP lesions were more frequently identified than partial lesions overall, the relative diagnostic gain

associated with the 70° arthroscope was greatest for partial or subtle lesions, indicating improved visualization of the posteromedial compartment. Senior surgeons demonstrated higher absolute sensitivity than junior surgeons, yet both groups benefited similarly from the use of the 70° optic. Together, these findings support the routine incorporation of 70° visualization during diagnostic arthroscopy for ACL-injured knees to minimize missed posteromedial meniscocapsular tears. Secondary analyses demonstrated excellent interobserver reliability across all experience levels, with kappa values exceeding 0.80 among senior surgeons and remaining substantial among junior evaluators. Agreement further improved when using the 70° arthroscope, suggesting that enhanced visualization reduces subjective variability between observers. The mixed-effects regression confirmed that both optic angle and surgeon experience independently influenced diagnostic performance, but no significant interaction was found—indicating that the benefit of the 70° scope was consistent regardless of expertise. In contrast, lesion subtype analysis revealed a significant Angle × Type interaction, with the 70° optic yielding the largest relative improvement in the detection of partial RAMP lesions. Importantly, no intraoperative complications occurred, underscoring the procedural safety of incorporating 70° visualization into standard diagnostic arthroscopy.

The RAMP lesions frequently accompany ACL ruptures[6]. However, it remains challenging to diagnose because no specific clinical examination findings have been established to date. MRI is commonly used as a diagnostic tool, and on T2 fat-saturated MRI sequences, the RAMP lesion appears as a detachment of the medial meniscus from the posteromedial capsule, often accompanied by bone edema[4,13].

A previous study reported that the sensitivity of MRI in detecting the RAMP lesion was 48%[11]. Furthermore, some studies have suggested that MRI is not capable of identifying the RAMP lesion[6,7]. In one cohort of 868 patients with an ACL rupture, the incidence of the RAMP lesion was found to be 16.6%, and different diagnostic rates were noted for MRI and arthroscopy[7]. Another study of 337 patients with ACL rupture reported an incidence of 13.1% for the RAMP lesion and a preoperative MRI sensitivity of 77%, which was higher than previously published findings[14].

Arthroscopy is considered the gold standard for diagnosing RAMP lesions. The first indicator is the displacement of the posteromedial horn of the medial meniscus during probing, despite an absence of visible tearing[15]. However, meniscocapsular detachment is often difficult to visualize through standard AL and AM portals. When only a 30° arthroscope is available, an additional PM viewing portal becomes critical for an accurate diagnosis[10].

In a study of 125 patients with ACL and medial meniscus rupture, the RAMP lesion was detected in 50 patients (40%). Among these, 29 patients (23.2%) were identified during the initial examination through the anterolateral portal, while no RAMP lesion was detected in 21 cases[16]. Other studies highlighted the pivotal role of the PM portal in detecting, classifying, and repairing the RAMP lesion[17–19]. Interestingly, a series of 301 patients was evaluated solely through anterior portals for visualization of the meniscocapsular junction, and the PM portal was deemed unnecessary[11]. In the present study, both 30° and 70° arthroscopes were found to be useful for diagnosing RAMP lesions with AM and AL portals. However, diagnostic arthroscopy performed without the PM portal was more effective when a 70° arthroscope was used.

In another study involving 224 patients with ACL rupture, the joint was initially examined through the AL portal with a 30° arthroscope to detect a RAMP lesion. A 70° arthroscope or PM portal was then applied in cases of suspected lesions, yet the diagnostic rates associated with different portals were not provided[15].

Another study focusing on hidden meniscus lesions reported a 50/302 rate of RAMP lesions, with 29 identified during the initial examination using a 30° arthroscope through

the AL portal. The remaining 21 lesions were detected only after debridement of overlying synovial or scar tissue, emphasizing the importance of probing the posterior knee joint through the PM portal[16].

In the described surgical technique, the intercondylar notch was inspected, and the 30° arthroscope was advanced, revealing a RAMP lesion at the 4 o'clock position around the posteromedial meniscotibial ligament. The posteromedial meniscotibial segment was then fully visualized after switching the arthroscope to the medial femoral condyle[20]. The 30° arthroscope was routinely used to evaluate the posteromedial compartment and medial meniscocapsular junction in the literature, and the use of both 30° and 70° arthroscopes through the transpatellar portal was suggested for RAMP lesion assessment. A PM portal was only recommended as a viewing portal if the lesion could not be entirely visualized[20]. Another study proposed the use of a 70° arthroscope through the AL portal to achieve a wider view and protect the posterior cruciate ligament[21].

Although the debate on portal selection persists, the angle of the arthroscope is also considered crucial in the intraoperative diagnosis of RAMP lesions. The viewing range of a 30° arthroscope is limited by both the anatomy and the location of the RAMP lesion[22].

This study has several limitations. It was conducted in a single center with a relatively limited number of patients and surgeons, which may limit the generalizability of the results. Although partial RAMP lesions were included and subclassified, their distinction from complete tears relied solely on intraoperative visualization and probing, which may still involve some degree of subjective interpretation. In addition, evaluation through the posterolateral portal was not performed, which might have provided additional confirmation of posteromedial findings. Furthermore, the cost-effectiveness of simultaneously employing two arthroscopes with different angles in the operating room setting was not assessed in this study. Despite these limitations, the results clearly demonstrate the diagnostic advantage of the 70° arthroscope in detecting both complete and partial RAMP lesions through standard anterolateral portals. Future multicenter studies with larger patient cohorts would be valuable to further confirm and consolidate these findings.

5. Conclusion

Although arthroscopy remains the gold standard for diagnosing RAMP lesions, using only a 30° arthroscope through the anterolateral portal may lead to missed findings, particularly in subtle or partial tears. Incorporating a 70° arthroscope during routine diagnostic arthroscopy provides a wider field of view, significantly improving the detection of both complete and partial RAMP lesions, regardless of surgeon experience.

Author Contributions: Methodology: B.K.; Investigation: M.A.C.; Validation: M.A.C.; Data curation: E.K., B.G.; Resources: S.S.; Visualization: S.S.; Writing – original draft: E.K., S.Y.; Writing – review and editing: B.K.; Supervision: M.E. All authors have read and approved the final version of the manuscript.

Funding: This research did not receive any specific grant from funding agencies in the public, commercial, or not-for-profit sectors.

Institutional Review Board Statement: This study was performed in line with the principles of the Declaration of Helsinki. Ethical approval was granted by the Institutional Ethics Committee of Istanbul Medeniyet University Göztepe Training and Research Hospital (Date: 15.08.2018, Approval No: 2018/0427).

Informed Consent Statement: Written informed consent was obtained from all individual participants included in the study.

Data Availability Statement: The datasets generated and/or analyzed during the current study are not publicly available due to ethical and legal restrictions related to patient confidentiality but are available from the corresponding author on reasonable request.

Acknowledgments: Not applicable.

Conflict of Interest: The authors declare that they have no conflict of interest.

References

1. Kongmalai P, Chernchujit B. Posterior Horn of Medial Meniscal Peripheral Capsular Lesion: The Arthroscopic Repair Technique Working in the Posterior Compartment. Arthrosc Tech. 2016;5(4):e763-e767. doi:10.1016/j.eats.2016.03.001.
2. Śmigielski R, Becker R, Zdanowicz U, Ciszek B. Medial meniscus anatomy-from basic science to treatment. Knee Surg Sports Traumatol Arthrosc. 2015;23(1):8-14. doi:10.1007/s00167-014-3476-5.
3. Gülenç B, Kemah B, Yalçın S, Sayar Ş, Korkmaz O, Erdil M. Surgical Treatment of Meniscal RAMP Lesion. J Knee Surg. 2020;33(3):255-259. doi:10.1055/s-0039-1677887.
4. Lorbach O, Kieb M, Herbort M, Weyers I, Raschke M, Engelhardt M. The influence of the medial meniscus in different conditions on anterior tibial translation in the anterior cruciate deficient knee. Int Orthop. 2015;39(4):681-687. doi:10.1007/s00264-014-2581-x.
5. Stephen JM, Halewood C, Kittl C, Bollen SR, Williams A, Amis AA. Posteromedial Meniscocapsular Lesions Increase Tibiofemoral Joint Laxity With Anterior Cruciate Ligament Deficiency, and Their Repair Reduces Laxity. Am J Sports Med. 2016;44(2):400-408. doi:10.1177/0363546515617454.
6. Bollen SR. Posteromedial meniscocapsular injury associated with rupture of the anterior cruciate ligament: a previously unrecognised association. J Bone Joint Surg Br. 2010;92(2):222-223. doi:10.1302/0301-620X.92B2.22974.
7. Liu X, Feng H, Zhang H, Hong L, Wang XS, Zhang J. Arthroscopic prevalence of RAMP lesion in 868 patients with anterior cruciate ligament injury. Am J Sports Med. 2011;39(4):832-837. doi:10.1177/0363546510388933.
8. Peltier A, Lording T, Maubisson L, Ballis R, Neyret P, Lustig S. The role of the meniscotibial ligament in posteromedial rotational knee stability. Knee Surg Sports Traumatol Arthrosc. 2015;23(10):2967-2973. doi:10.1007/s00167-015-3751-0.
9. Chahla J, Dean CS, Moatshe G, Mitchell JJ, Cram TR, Yacuzzi C, et al. Meniscal Ramp Lesions: Anatomy, Incidence, Diagnosis, and Treatment. Orthop J Sports Med. 2016;4(7):2325967116657815. doi:10.1177/2325967116657815.
10. Chen Z, Li WP, Yang R, Song B, Jiang C, Hou JY, et al. Meniscal Ramp Lesion Repair Using the FasT-Fix Technique: Evaluating Healing and Patient Outcomes with Second-Look Arthroscopy. J Knee Surg. 2018;31(8):710-715. doi:10.1055/s-0037-1606378.
11. DePhillipo NN, Cinque ME, Chahla J, Geeslin AG, Engebretsen L, LaPrade RF. Incidence and Detection of Meniscal Ramp Lesions on Magnetic Resonance Imaging in Patients With Anterior Cruciate Ligament Reconstruction. Am J Sports Med. 2017;45(10):2233-2237. doi:10.1177/0363546517704426.
12. Klein E, Solomon D. Editorial Commentary: Arthroscopy Is the Gold Standard for Diagnosis of Meniscal Ramp Lesions: Magnetic Resonance Imaging Also May Be Helpful. Arthroscopy. 2023;39(3):600-601. doi:10.1016/j.arthro.2022.12.007.
13. Greif DN, Baraga MG, Rizzo MG, Mohile NV, Silva FD, Fox T, et al. MRI appearance of the different meniscal RAMP lesion types, with clinical and arthroscopic correlation. Skeletal Radiol. 2020;49(5):677-689. doi:10.1007/s00256-020-03381-4.
14. Arner JW, Herbst E, Burnham JM, Soni A, Naendrup JH, Popchak A, et al. MRI can accurately detect meniscal RAMP lesions of the knee. Knee Surg Sports Traumatol Arthrosc. 2017;25(12):3955-3960. doi:10.1007/s00167-017-4523-9.
15. Seil R, Mouton C, Coquay J, Hoffmann A, Nührenbörger C, Pape D, et al. Ramp lesions associated with ACL injuries are more likely to be present in contact injuries and complete ACL tears. Knee Surg Sports Traumatol Arthrosc. 2018;26(4):1080-1085. doi:10.1007/s00167-017-4598-3.
16. Sonnery-Cottet B, Conteduca J, Thaunat M, Gunepin FX, Seil R. Hidden lesions of the posterior horn of the medial meniscus: a systematic arthroscopic exploration of the concealed portion of the knee. Am J Sports Med. 2014;42(4):921-926. doi:10.1177/0363546514522394.
17. Liu X, Zhang H, Feng H, Hong L, Wang XS, Song GY. Is It Necessary to Repair Stable Ramp Lesions of the Medial Meniscus During Anterior Cruciate Ligament Reconstruction? A Prospective Randomized Controlled Trial. Am J Sports Med. 2017;45(5):1004-1011. doi:10.1177/0363546516682493.

18. Thaunat M, Jan N, Fayard JM, Kajetanek C, Murphy CG, Pupim B, et al. Repair of Meniscal Ramp Lesions Through a Posteromedial Portal During Anterior Cruciate Ligament Reconstruction: Outcome Study With a Minimum 2-Year Follow-up. Arthroscopy. 2016;32(11):2269-2277. doi:10.1016/j.arthro.2016.02.026.
19. Ahn JH, Kim SH, Yoo JC, Wang JH. All-inside suture technique using two posteromedial portals in a medial meniscus posterior horn tear. Arthroscopy. 2004;20(1):101-108. doi:10.1016/j.arthro.2003.11.008.
20. Negrín R, Reyes NO, Iñiguez M, Pellegrini JJ, Wainer M, Duboy J. Meniscal Ramp Lesion Repair Using an All-Inside Technique. Arthrosc Tech. 2018;7(3):e265-e270. doi:10.1016/j.eats.2017.09.001.
21. Buyukdogan K, Laidlaw MS, Miller MD. Meniscal Ramp Lesion Repair by a Trans-septal Portal Technique. Arthrosc Tech. 2017;6(4):e1379-e1386. doi:10.1016/j.eats.2017.05.029.
22. Bae BS, Yoo S, Lee SH. Ramp lesion in anterior cruciate ligament injury: a review of the anatomy, biomechanics, epidemiology, and diagnosis. Knee Surg Relat Res. 2023;35(1):23. doi:10.1186/s43019-023-00197-z.