JoCASS
Çukurova Anestezi ve Cerrahi Bilimler Dergisi
2018 Adana

A NEW SURGICAL TECHNIQUE FOR GRAFT ANASTOMOSIS TO THE PORCELAIN AORTA

PORSELEN AORTAYA GREFT ANASTOMOZU İÇİN YENİ BİR CERRAHİ TEKNİK

Süreyya Talay[1], Baran Şimşek[2], Kadir Arslan[3]

1 Department of Cardiovascular Surgery, 29 Mayıs States Hospital, Ankara, Turkey
2 Department of Cardiovascular Surgery, Medicana International, Istanbul, Turkey
3 Department of Cardiovascular Surgery, Mugla Education and Research Hospital, Mugla, Turkey

Sorumlu Yazar/Corresponding Author: Süreyya Talay E-mail: suereyyatalay@gmail.com
Geliş Tarihi/Received: 24.06.2021 Kabul Tarihi-Accepted: 25.10.2021 Available Online Date/Çevrimiçi Yayın Tarihi: 31.12.2021
Cite this article as: Talay S, Şimşek B, Arslan K. Fear, A New Surgical Technique For Graft Anastomosis To The Porcelain Aorta J Cukurova Anesth Surg. 2021;4(3):197-203.
Doi: 10.36516/jocass.2021.89

Abstract

Widespread and severe calcification of the ascending aorta and the presence of a porcelain aorta, which appears as a larger surgical obstacle, is an important problem that can have catastrophic consequences for graft proximal anastomoses. In this study, as a new idea, we tried to explain an original surgical technique that was not previously described in the medical literature. Basically, this is a suggestion for a new surgical technique. In an In-vitro working environment, ascending aorta-saphenous vein anastomosis was performed using human saphenous vein samples in the bovine heart with our new surgical technique. After the anastomosis was completed, the aorta was controlled with saline solution given with high pressure. It was observed that there was no leak from the anastomosis line. We believe that in the presence of porcelain aorta, especially during coronary surgery, proximal anastomosis of the saphenous graft aorta can be applied to the porcelain aorta with this new surgical technique. Thus, anastomoses can be applied without placing side clamps in the aorta and avoiding side clamp complications.

Keywords: Porcelain aorta, graft anastomosis, surgical innovation

Öz

Çıkan aortun yaygın ve şiddetli kalsifikasyonu ve daha büyük bir cerrahi engel gibi görünen porselen aortun varlığı, greft proksimal anastomozlar için katastrofik sonuçlar doğurabilen önemli bir sorundur. Bu çalışmada yeni bir fikir olarak tıp literatüründe daha önce tanımlanmamış özgün bir cerrahi tekniği açıklamaya çalıştık. Temel olarak bu, yeni bir cerrahi teknik için bir öneridir. Yeni cerrahi tekniğimiz ile in vitro çalışma ortamında sığır kalbinde insan safen ven örnekleri kullanılarak asendan aort-safenöz ven anastomozu yapıldı. Anastomoz tamamlandıktan sonra yüksek basınçla verilen salin solüsyonu ile aorta kontrol edildi. Anastomoz hattından kaçak olmadığı görüldü. Bu yeni cerrahi teknik ile porselen aorta varlığında özellikle koroner cerrahi sırasında safen greft aortanın proksimal anastomozunun porselen aortaya uygulanabileceğini düşünmekteyiz. Böylece aortaya yan klemp konulmadan ve yan klemp komplikasyonlarından kaçınılmadan anastomoz uygulanabilmektedir.

Anahtar Kelimeler: Porselen aort, greft anastomozu, cerrahi yenilik

©Copyright 2021 by Çukurova Anestezi ve Cerrahi Bilimler Dergisi - Available online at http://dergipark.gov.tr/jocass

Introduction

Porcelain aorta is an important surgical problem, especially during coronary surgery[1]. Cannulation during surgery, cross-clamping, cardioplegia, and proximal anastomosis of the graft with a side clamp can be an important source of mortality and morbidity. Any manipulation of the porcelain aorta may produce distal plate embolization and partial or complete tears in the aorta. These conditions appear as a challenge for every cardiac surgeon in daily practice[2-3]. During cardiopulmonary bypass induction, different surgical solutions such as supra-coronary internal aortic balloon occlusion as an aortic cross clamp were developed for reaching cardiac arrest while artery cannulation was performed from different regions such as the femoral or axillary artery.

However, saphenous graft anastomosis in porcelain aorta is still a problem. For this purpose, although extranatomic bypass graft options and/or 'No Touch to Aorta' anastomosis options are applied, surgical options are limited when anastomosis of saphenous grafts to the porcelain aorta is mandatory[4]. For this purpose, alternative methods such as 'PAS-Port proximal anastomosis systems' and 'Heartstring devices' have been defined in the medical literature to perform proximal anastomosis to the porcelain aorta. In the surgical variation we propose in this study, the graft is anastomosed to the aorta with a routine propylene suture using a continuous anastomosis technique and a different surgical equipment is not required as in the PAS-Port mechanism[5]. As an alternative to PAS-Port system, Thourani et al demonstrated and advocated 'Heartstring device' for a solution to porcelain aorta cases. In this device, there is a proximal seal, a delivery device with an aortic puncher to deliver a haemostatic seal designed to enable the graft anastomosis when a side clamp is not applicable. Their cases were mostly (93%) off-pump coronary surgery and a 1.2% rate of stroke was observed. The latter data is reported to be evidence that Heartstring device could be useable with a safe neurological complication risk equal to elective 'non-porcelain' cases. Both devices of PAS-Port and Heartstring are reported to present a safe anastomosis technique in clampless conditions[6].

Material and Method

We studied our new ascending aorta-vascular graft anastomosis technique in-vitro using bovine heart and human saphenous vein grafts.

During routine coronary surgery, after cardioplegic arrest and distal coronary anastomoses are completed, an appropriate area on the porcelain aorta with sufficient width for anastomosis is decided. Similarly, it may be possible to apply this technique when performing off-pump coronary surgery other than cardiac arrest. Considering the difficulty of applying side clamps in calcific aorta in the presence of high pressure, the anastomosis technique that we recommend being applied especially in off-pump coronary surgery cases will provide great convenience. On the other hand, we think it will be possible to apply it with a similar ease under CPB.

- *Surgical technique or experimental design*

In the first stage, vascular graft anastomosis is performed without a side clamp application for saphenous graft anastomosis as in our example. At the appropriate anastomosis site, the proximal end of the saphenous graft is prepared for anastomosis. Proximal anastomosis is performed to aorta without an aortic puncher and an ostium. We anastomosed our saphenous graft to the aorta with continuous suture technique with 6/0 propylene suture. Before the last suture of the anastomosis, our graft can be de-aired with retrograde coronary flow.

©Copyright 2021 by Çukurova Anestezi ve Cerrahi Bilimler Dergisi - Available online at http://dergipark.gov.tr/jocass

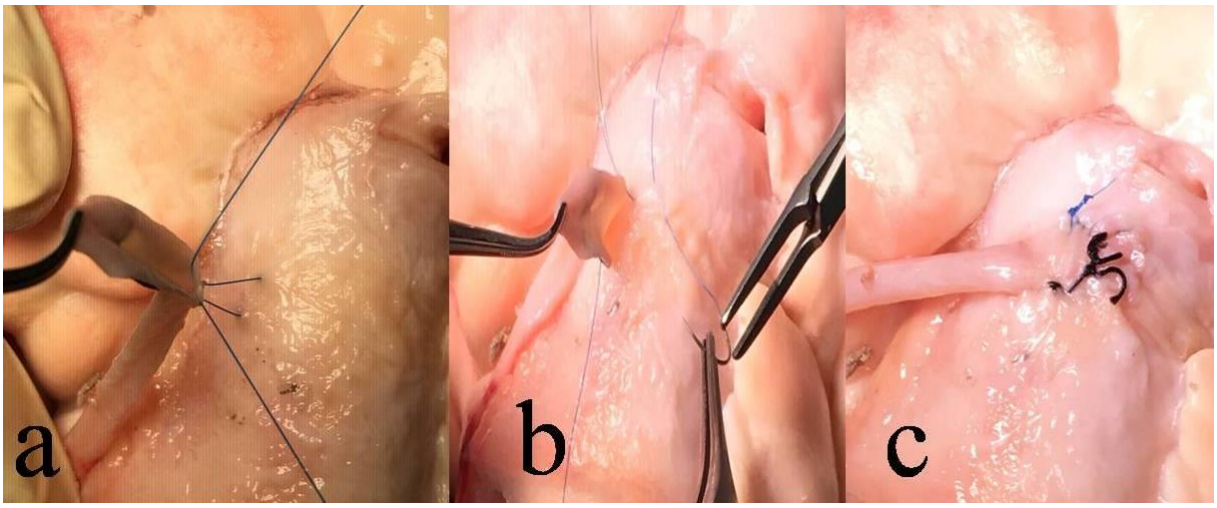

Figure 1. Graft proximal anastomosis to aorta

When there is not enough retrograde flow, it is possible to fill the graft with antegrade SF or blood volume. (Figure 1)
The suture loop and anastomotic line should be planned directly into the relatively uncalcified area detected by palpation where strong suture lines of reinforced alloy such as Thungsten can pass through this anastomotic site. The area inside this suture loop should likewise include a soft vascular area to allow puncher application.

After the cardiac arrest is terminated by routine practice or high intra-aortic blood pressure in the aorta as in off-pump coronary surgery, two bulldog clamps are applied to the saphenous vein graft at a distance of 3-4 cm to proximal anastomosis and close the anastomosis line. The saphenous graft is incised to allow 4 mm aortic puncher to enter. (Figure 2)

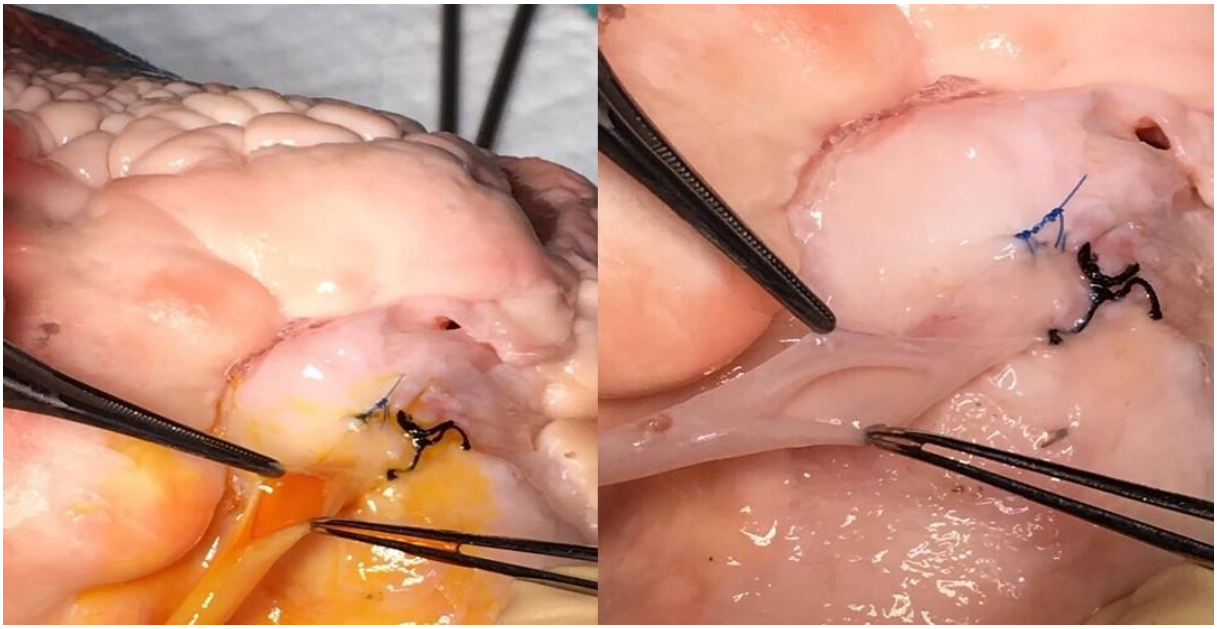
Figure 2. Saphenous vein incision between bulldog clamps

©Copyright 2021 by Çukurova Anestezi ve Cerrahi Bilimler Dergisi - Available online at http://dergipark.gov.tr/jocass

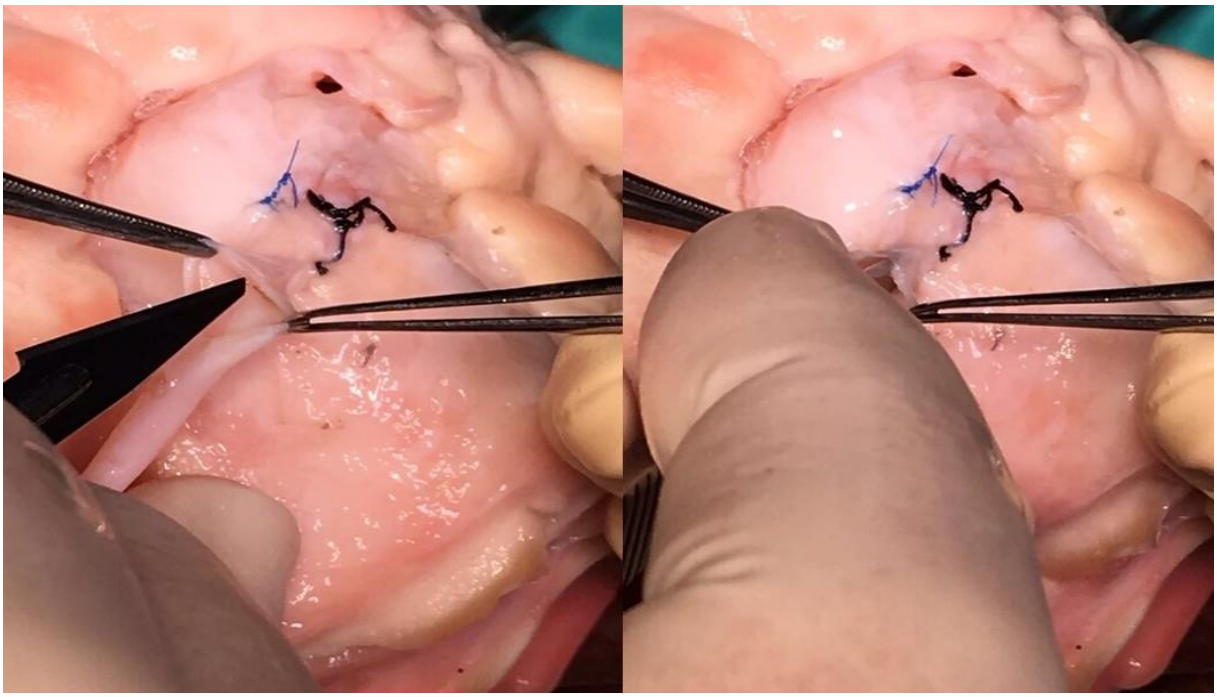

Figure 3. Aortic incision as a preparation for aortic puncher, via saphenous vein, intra-luminally

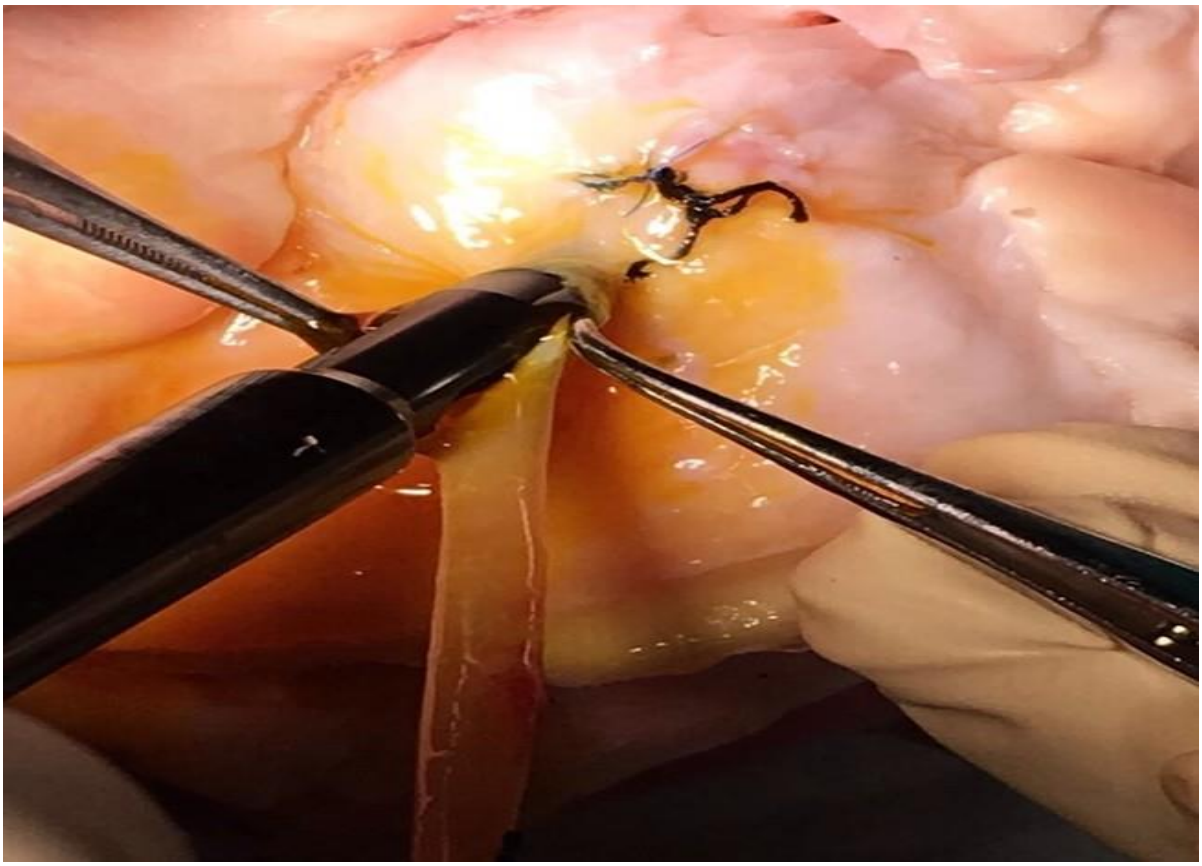

Figure 4. Aortic puncher via saphenous vein, intra-luminally

©Copyright 2021 by Çukurova Anestezi ve Cerrahi Bilimler Dergisi - Available online at http://dergipark.gov.tr/jocass

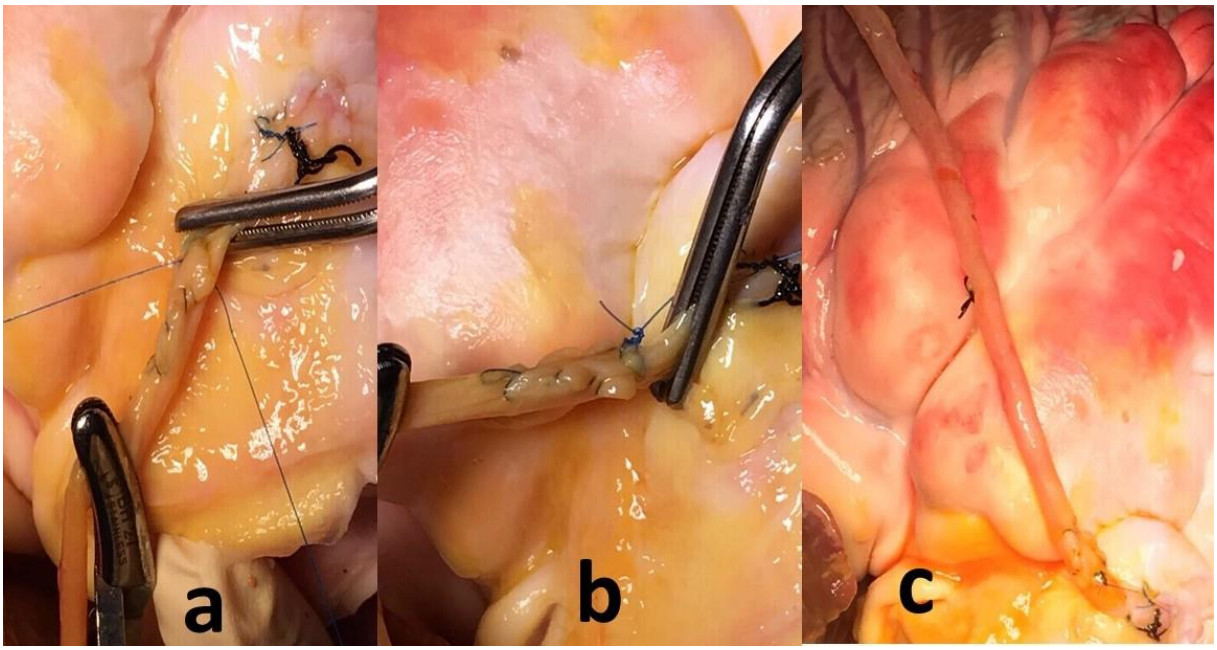

Figure 5. Saphenous vein incision closure and suturation

By removing the proximal bulldog clamp, an incision is made through the saphenous graft with an 11-sized scalpel to allow puncher application in the aorta. (Figure 3)
Aortic puncher advanced intra-luminally in the saphenous vein to aorta. A complete aortic button that is wide enough to allow high arterial flow from the aorta into the graft is removed by the bites of aortic puncher. (Figure 4)
By replacing the proximal bulldog clamp, the saphenous graft incision made for the aortic puncher is closed with 6/0 propylene sutures. Then the aortic side bulldog clamps on the saphenous graft is removed, de-airing can be repeated in standard practice with a thin syringe tip before removing the distal bulldog clamp. (Figure 5)

Results

In our in-vitro study, after these stages, we controlled our anastomosis line by giving saline with high pressure from the aorta. We observed that our anastomosis was intact and we observed a strong flow on the coronary side. When a leak is observed in the anastomosis line, it will be possible to add strengthening sutures as in routine practice.
With the surgical anastomosis technique we recommended in this study, grafts can be made to the aorta without the need for a side clamping. It will be sufficient to have an area suitable for anastomosis on the aorta and generally such an area without hard plaque can almost always be found.

Discussion

The summary our new surgical technique hereby we are trying to explain is; a direct graft proximal anastomosis prior to an aortic anastomotic osteal opening, intra-luminal aortic puncher application via a saphenous incision and finally primary suturing of saphenous graft incision. In our opinion, this will result in a safe proximal anastomosis possibility in porcelain aorta cases.

©Copyright 2021 by Çukurova Anestezi ve Cerrahi Bilimler Dergisi - Available online at http://dergipark.gov.tr/jocass

One of the important points to consider regarding this surgical technique we propose is that the anastomotic sutures do not pass through the osteal space opened with the puncher as in the conventional technique. There are two puncture points on each suture line as entry and exit. The emergence of a dissection line along the aorta line under increased intraluminal pressure from these points is a risk to be considered. Nevertheless, the risk of side clamp application in the porcelain aorta is higher in every respect.
It will be important to determine the area where the puncher will be applied by palpation before the procedure for opening a full layer aortic button.
In addition, it is clear that there will be endothelial damage due to incision and restoration in the saphenotomy line in the saphenous graft anastomosis line. In cases with insufficient diameter width, a patchplasty can be applied as an alternative. During de-airing manoeuvres there is a risk of early graft re-stenosis similar to saphenous needle puncture. Surely, saphenous vein graft incision, which is not included in routine surgery on the coronary saphenous graft, may increase the tendency to complications due to early re-stenosis and intra-graft endothelial damage near the anastomosis site.
However, in a difficult situation such as porcelain aorta, we think that the proximal anastomosis of the saphenous vein to aorta is a better option than the alternative to the LIMA body. The latter is generally suggested in the literature as a solution in these patients[7]. Generally, the solution recommended in porcelain aorta is reported as extra-anatomic anastomoses such as T-graft. Off-pump is recommended as a surgical suggestion. However, difficulties are encountered in this technique in Circumflex artery anastomoses. Another recommendation is LIMA-RIMA revascularization.
A study from Amorim et al[8] presented a novel classification for porcelain aorta. Accordingly, severe calcification of the ascending aorta with a circumferential pattern is suggested to be elaborated in 3 different types. These categories are defined as Type IA (aorta with no possible clamping), Type IB (aorta with possible clamping at increased risk) and Type II (aortic arch and/or descending aorta calcification). Partially, a side clamp application may be possible in Type IB and Type II patients with a higher probability. At this point, the distribution of calcification plates and the location of the intact aortic tissue are decisive.
The surgical anastomosis technique we recommend can be planned in Type IA and Type IB cases where it is possible in areas with sufficient solid tissue for anatomy. In the presence of Type II aorta, side clamp compliance should be evaluated first if applicable in both on and off pump coronary surgery.

Author contributions

All authors contributed to the study conception and design.

Conflict of Interest

The authors declare that they have no conflict of interest.

Funding

Authors declared no financial support.

Ethical approval

This study, in which patients participated on a voluntary basis, was conducted in accordance with all ethical procedures /standards and the Declaration of Helsinki.
Ankara 29 Mayıs Devlet Hastanesi 10/07/2021

References

1. Ozatik MA, Gol MK, Fansa I, et al. Risk factors for stroke following coronary artery bypass operations. J Card Surg 2005; 20:52–57. https://doi.org/10.1111/j.0886-0440.2005.200384.x
2. Sirin G, Sarkislali K, Konakci M, et al. “Extraanatomical coronary artery bypass grafting in patients with severely atherosclerotic (Porcelain) aorta,” Journal of Cardiothoracic

Surgery, 2013; vol. 8, no. 1, article 86. https://doi.org/10.1186/1749-8090-8-86
3. Uyar I, Demir T, Polat A, et al. "Innominate artery as an alternative site for proximal anastomoses in patients with a severely calcified aorta," Journal of Cardiac Surgery, 2013; vol. 28, no. 3, pp. 228–32. https://doi.org/10.1111/jocs.12112
4. Yay K, Hanedan MO, Başar V, et al.Porcelain aorta: a new indication for on-pump beating heart mitral valve replacement.Turkish Journal of Thoracic and Cardiovascular Surgery,2012;20(1):122-4.
5. Puskas JD, Halkos ME, Balkhy H, et al. Evaluation of the PAS-Port proximal anastomosis system in coronary artery bypass surgery (the EPIC trial). J ThoracCardiovascSurg 2009; 138:125—32. https://doi.org/10.1016/j.jtcvs.2009.02.017
6. Thourani VH, Razavi SA, Nguyen TC, et al. Incidence of Postoperative Stroke Using theHeartstring Device in 1,380 Coronary Artery BypassGraft Patients With Mild to Severe Atherosclerosisof the Ascending Aorta. Annals of Thoracic Surgery, 2014;97(6):2066-72. https://doi.org/10.1016/j.athoracsur.2014.02.044
7. Demirsoy E, Unal M, Arbatlı H, et al. Extra-anatomic coronary artery bypass graftings in patients with porcelain aorta. J Cardiovasc Surg. 2004, 45: 111-5.
8. Amorim PA, Penov K, Lehmkul L,et al. Not all porcelain is the same: Classification of circular aortic classification (Porcelain aorta) according to the impact on therapeutic approach. ThoracCardiovascSurg 2013;61:559-63. https://doi.org/10.1055/s-0032-1333204

©Copyright 2021 by Çukurova Anestezi ve Cerrahi Bilimler Dergisi - Available online at http://dergipark.gov.tr/jocass