JoCASS
Çukurova Anestezi ve Cerrahi Bilimler Dergisi
2018 Adana

PAGET'S DISEASE OF THE BREAST: CLINICAL-PATHOLOGICAL FINDINGS AND SURVEILLANCE

MEMENİN PAGET HASTALIĞINDA KLİNİK-PATOLOJİK BULGULAR VE TAKİP SONUÇLARI

Tevfik Avcı[1], Hakan Yabanoğlu[2], Murathan Erkent[1], Pelin Börcek[3], Murat Kuş[2]

1 Başkent Üniversitesi Tıp Fakültesi Genel Cerrahi Ana Bilim Dalı, Ankara, Türkiye
2 Başkent Üniversitesi Adana Dr. Turgut Noyan Uygulama ve Araştırma Merkezi Genel Cerrahi Ana Bilim Dalı, Adana, Türkiye
3 Başkent Üniversitesi Tıp Fakültesi Patoloji Ana Bilim Dalı, Ankara, Türkiye

Sorumlu Yazar/Corresponding Author:Tevfik Avcı E-mail: tevfikavci@yahoo.com
Geliş Tarihi/Received: 15.12.2020 Kabul Tarihi-Accepted: 23.12.2020 Available Online Date/Çevrimiçi Yayın Tarihi: 31.12.2020
Cite this article as: Avcı T, Yabanoğlu H, Erkent M, Börcek P, Kuş M. Paget's Disease of the Breast: Clinical-Pathological Findings and Surveillance. J Cukurova Anesth Surg. 2020;3(3):230-8. *Doi:* 10.36516/jocass.2021.60
0000-0001-5225-959X, 0000-0002-1161-3369, 0000-0002-3592-5092, 0000-0001-8565-0667, 0000-0001-6529-7579

Abstract

Objective: In this study we aimed to examine the clinicopathological findings and surveillance of patients with Paget's disease of the breast (PD).

Materials and Method: The medical records of 49 patients diagnosed and treated with PD at Başkent University Faculty of Medicine, General Surgery Clinic between January 2013 and October 2018 were retrospectively analyzed.

Results: Mean age of the patients was 52.9±13.6 (26-90). The majority of the patients were women (n:45, 91.8%). The most frequent symptom at the time of admission was palpable mass (n:22, 44.9%). Modified radical mastectomy (MRM) was performed in 31 patients (63.3%), simple mastectomy in 16 patients (32.6%) and breast conserving surgery in 2 patients (4.1%). Sentinel lymph node biopsy (SLNB) in 7 (14.2%) patients and axillary lymph node dissection was performed in one patient. Invasive ductal carcinoma constituted the major histology concomitant with Paget Disease (89.8%). Lymph node involvement (LNI) was present in 29 (59.2%) patients. Palpable mass noticed by the patient and mass size over 20 mm was statistically associated with LNI (p:0.004 for both). Over 50 years of age was associated with a lower recurrence free survival (RFS) (39.2 months vs 64.1 months, p:0.012). RFS was lower in Her2 negative patients (p:0.002).

Conclusion: PD is rare, it is an important disease that should not be missed. Although Her2 positivity is generally considered as a poor prognostic factor in breast cancers, we think that those with Her2 negativity may also have a poor prognosis in PD.

Keywords: Diagnosis, male breast neoplasm, Paget's disease of breast, prognosis

©Copyright 2020 by Çukurova Anestezi ve Cerrahi Bilimler Dergisi - Available online at http://dergipark.gov.tr/jocass

Öz
Amaç: Bu çalışmada, memenin Paget hastalığı (PH) tanısı olan hastaların klinik ve patolojik verilerini ve takip sonuçlarını incelemeyi amaçladık. Gereç ve Yöntem: Ocak 2013- Ekim 2018 tarihleri arasında Başkent Üniversitesi Tıp Fakültesi Genel Cerrahi Kliniği'nde PH tanısı ve tedavisi alan 49 hastanın tıbbi kayıtları retrospektif olarak incelendi.
Bulgular: Hastaların ortalama yaşı 52.9 ± 13.6 (26-90) idi. Hastaların çoğu kadındı (45/49, %91,8). Başvuru anında en sık görülen semptom ele gelen kitle idi (n: 22, %44,9). 31 hastaya (%63,3) modifiye radikal mastektomi (MRM), 16 hastaya (%32,6) basit mastektomi ve 2 hastaya (%4,1) meme koruyucu cerrahi uygulandı. Yedi (%14,2) hastaya sentinel lenf nodu biyopsisi (SLNB) ve bir hastaya aksiller lenf nodu diseksiyonu yapıldı. İnvazif duktal karsinom, PH (%89,8) ile görülen majör histolojiyi oluşturdu. Lenf nodu tutulumu (LNI) 29 (%59,2) hastada mevcuttu. Hasta tarafından fark edilen ele gelen kitle ve 20 mm'nin üzerindeki kitle boyutu LNI ile istatistiksel olarak ilişkiliydi (her ikisi için p: 0,004). 50 yaş üstü, daha düşük hastalıksız sağ kalım ile ilişkilendirildi (39,2 aya karşı 64,1 ay, p: 0,012). Hastalıksız sağ kalım, Her2 negatif hastalarda daha düşüktü (p: 0.002).
Sonuç: PH nadir görülen ancak gözden kaçmaması gereken önemli bir hastalıktır. Her2 pozitifliği genellikle meme kanserlerinde kötü prognostik faktör olarak kabul edilmekle birlikte, Her2 negatifliği olanların da PH'de kötü prognoza sahip olabileceğini düşünüyoruz.

Anahtar Kelimeler: Erkek meme neoplazmları, memenin Paget hastalığı, prognoz

Introduction

Paget's disease of the breast (PD) is a rare disease of the nipple-areola complex (NAC), usually an underlying breast carcinoma is thought to be due to carcinomatous cell migration to the nipple via intraepidermal route[1]. It constitutes 0.5-5% of all breast carcinomas[2]. PD is characterized by ulcerated, crusty or scaly lesions on the nipple or extending to the areola. It may be difficult to make the diagnosis at the time of presentation because mammography can be reported normally in 50% of cases[3]. In addition, some studies have shown that PD may actually be associated with an underlying ductal carcinoma or lobular carcinoma[4-6]. Biopsy should be done in suspected cases. After the biopsy, the diagnosis is made after immunohistochemical staining and histopathological examinations. Immunohistochemistry should be done to differentiate from other intraepidermal clear cell neoplasms (Bowen's disease, Pagetoid melanoma)[7].

The aim of this study is to examine the diagnosis, treatment and risk factors of patients with PD of the breast and to share the experiences of 49 patients gathered in a single center related to this rare disease with the scientific community.

Material and Methods

This is a retrospective case series including a single institute experience of Paget's Disease of Breast. Study which was conducted in accordance with the principles of the Declaration of Helsinki. 49 patients who were diagnosed with Paget's disease of breast between January 2013 and October 2018 were included. Inclusion and exclusion criteria are shown in figure 1. This study was approved by Baskent University Institutional Review Board (Project no: KA20/439) and supported by Baskent University Research Fund.

Age, histopathological results, surgical approaches and imaging results were analyzed from the patient records. Morbidity and mortality of patients was obtained from hospital system.

Patients underwent either breast conserving surgery (BCS) including a complete excision of the nipple-areola complex or mastectomy, with or without

©Copyright 2020 by Çukurova Anestezi ve Cerrahi Bilimler Dergisi - Available online at http://dergipark.gov.tr/jocass

sentinel lymph node biopsy and/or axillary lymph node dissection.

Statistical analyses were performed using the statistical software package SPSS version 22.0 (SPSS, Inc. Chicago, IL). The data were expressed as median and range for continuous variables. Binary variables were reported as counts and percentages. Cross-tab analyses were used for sensitivity and specificity calculations. Categorical variables were compared using the χ^2 test or Fisher's exact test where appropriate. The Kaplan–Meier test was used to identify differences between curves and in analysis of risk factors for recurrence. Multivariate analysis calculated with cox regression test. Survival was measured from the time of diagnosis. A p-value of less than 0.05 was considered statistically significant.

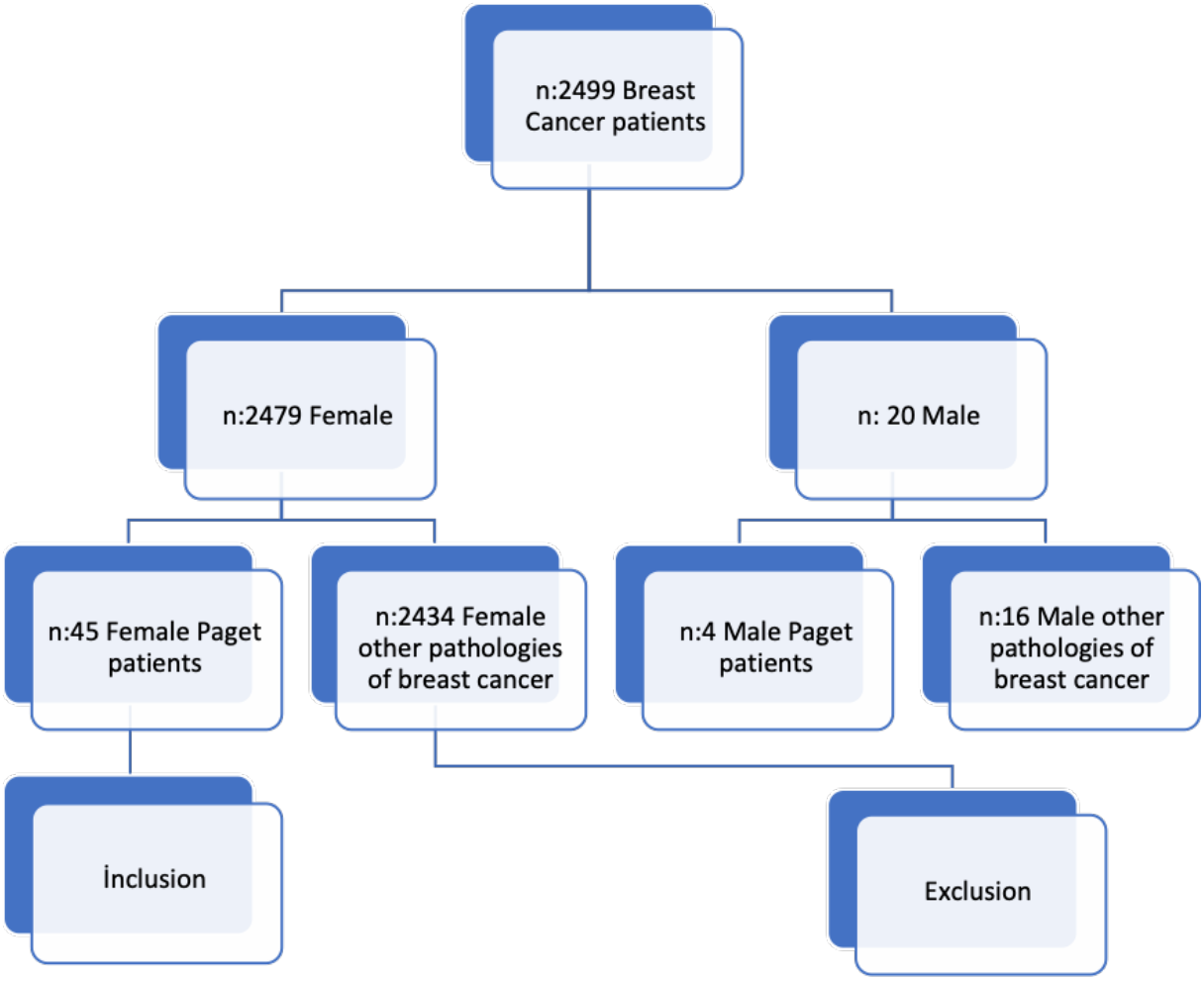

Figure 1. Flowchart of inclusion and exclusion criteria

©Copyright 2020 by Çukurova Anestezi ve Cerrahi Bilimler Dergisi - Available online at http://dergipark.gov.tr/jocass

Results

Mean age of the patients was 52.9±13.6 (26-90). The majority of the patients were women with a portio of 91.8% (45/49) The most frequent symptom at the time of admission was palpable mass followed by excoriation of epidermis and skin dimpling: 22(44.9%), 14 (28.6%) and 7 (14.3), respectively. General characteristics of patients was summarized in table 1.

Modified radical mastectomy (MRM) was performed in 31 patients (63.3%), simple mastectomy in 16 patients (32.6%) and breast conserving surgery in 2 patients (4.1%) was performed. Sentinel lymph node biopsy (SLNB) was performed in 7 (14.2%) and axillary lymph node dissection was performed in one patient. Distribution of surgical approaches were shown in table 2.

Table 1. Characteristics of Patients

	Mean±Std.Dev.	**Median (Range)**
Age	52.9±13.6	53 (26-90)
	N	**%**
Any complaint		
Present	47	95.9
Absent	2	4.1
Distribution of Complaints		
Wound	14	28.6
Nipple discharge	6	12.2
Palpable Mass	22	44.9
Skin dimpling	7	14.3
Pain	6	12.2
Family History		
Present	8	16.3
Absent	41	83.7
Pre-operative Topical Treatment		
Present	3	6.1
Absent	46	93.9

Table 2. Surgical approaches

	n	**%**
Modified Radical Mastectomy	28	57.1
Modified Radical Mastectomy + Latissimus Dorsi Flap	1	2.0
Modified Radical Mastectomy + Implant	1	2.0
Bilateral Modified Radical Mastectomy	1	2.0
Simple Mastectomy	10	20.4
Simple Mastectomy + Sentinel Lymph Node Biopsy	6	12.2
Breast conserving surgery + Axillary Lymph Node Dissection	1	2.0
Breast conserving surgery + Sentinel Lymph Node Biopsy	1	2.0

©Copyright 2020 by Çukurova Anestezi ve Cerrahi Bilimler Dergisi - Available online at http://dergipark.gov.tr/jocass

Invasive ductal carcinoma constituted the major histology concomitant with PD (89.8%). Lobular carcinoma was the second frequent histology (18.4%) and all of them were also accompanied by invasive ductal carcinoma. Lymph node involvement (LNI) was present in 29 (59.2%) patients. Palpable mass noticed by the patient and mass size of >20mm was statistically associated with LNI in univariate analysis (p:0.004 for both). LNI was present in 18/22 (81.8%) of patients who noticed a palpable mass while in 11/27 (40.7%) who did not. Moreover LNI rate was 74.2% when mass size was >20 mm and 31.3% when mass size was ≤20 mm. Besides LNI was not associated with any of molecular marker expression, histology or age (p>0.05, for all).

26 patients continued their follow-up in our center. Only one of these patients died of disease in the follow-up thus overall survival analysis was not performed. Risk factors were evaluated with univariate analysis. Age >50 years old was associated with a lower recurrence free survival (RFS) (39.2 months vs 64.1 months, p:0.012). Mass size (>20mm) was also associated with a clinically lower RFS (40.6 months vs. 62.5 months) whereas this difference was not statistically significant (p:0.055). In analysis of expression of the molecular markers, positivity of any molecular marker was not associated with recurrence. RFS was lower in Her2 negative patients (p:0.002). Univariate analyses were summarized in table 4.

Table 3. Histopathological findings

		n	%
Expression rate of molecular markers			
Steroid hormone receptors	ER	12	24.5
	PR	12	24.5
Oncoproteins	Her2	23	46.9
	Cyclin D1	31	63.3
	Bcl2	27	55.1
Intermediate filaments	Vimentin	12	24.5
	Cytokeratin	49	100
Tumor suppressors	P53	30	61.2
Distribution of Histologic Results Concomitant with Paget			
Invasive Ductal Carcinoma		34	69.4
Ductal Carcinoma Insitu		3	6.1
Invasive Ductal + Invasiv Lobular Carcinoma		9	18.4
Invasive Ductal + Mucinous Carcinoma		1	2.0
Invasive Papillary Carcinoma		1	2.0
Paget's disease only		1	2.0

©Copyright 2020 by Çukurova Anestezi ve Cerrahi Bilimler Dergisi - Available online at http://dergipark.gov.tr/jocass

Table 4. Univariate analysis of risk factors for recurrence

	Univariate Survival Analysis			
	Mean Survival (Months-Estimate)	**95% CI**		**p-value**
Age (year)				
≤50	64.1	54.1	74.1	**0.012**
>50	39.2	27.5	50.9	
Mass Size				
≤20mm	62.5	50.6	74.3	**0.055**
>50mm	40.6	29.5	51.7	
Lymph Node Status				
Positive	44.1	33.1	55.2	**0.214**
Negative	48.2	45.2	71.2	
ER				
Positive	42.7	31.7	53.7	**0.235**
Negative	57.0	46.1	67.9	
PR				
Positive	43.2	32.5	54.0	**0.314**
Negative	56.3	44.8	67.7	
Her2				
Positive	58.4	49.7	67.2	**0.002**
Negative	21.5	16.3	26.7	
Cyclin-D1				
Positive	58.2	48.2	68.2	**0.076**
Negative	33.0	20.9	45.1	
Bcl-2				
Positive	49.2	40.6	57.8	**0.751**
Negative	51.6	35.7	67.5	
Vimentin				
Positive	57.6	45.0	70.2	**0.548**
Negative	45.7	32.4	59.1	
P53				
Positive	45.3	35.8	54.8	**0.908**
Negative	51.0	36.1	65.8	

©Copyright 2020 by Çukurova Anestezi ve Cerrahi Bilimler Dergisi - Available online at http://dergipark.gov.tr/jocass

Discussion

Paget's disease is a rare disease. It is an intraepithelial adenocarcinoma that can be seen in the mammary or extrammary[8]. In this study, PD of the breast were analyzed. PD is more common in the fifth or sixth decade of life but can also be seen in adults and elderly[9]. In our study, our patient population was compatible with the literature. PD is more common in females than males, but it can also be seen in males. In a review published in the literature in 2016, only 57 cases of male Paget's disease were reported so far[10]. The unique aspect of our study from other studies was that we had 4 patients with male PD. The most common symptom may be ulcerated, crusty or scaly lesions in the nipple that can extend to the areola, and there may be shrinkage in the nipple, especially bloody nipple discharge should be considered[11]. Patients often suffer from pain, itching and burning. For this reason, patients who apply to dermatology are treated with atopic dermatitis pre-diagnosis[12-15]. In our series, the most common reason for application was palpable mass. There was a decreasing frequency of application with skin lesions on the nipple.

Surgery should be considered in the first place as a treatment[2]. Mastectomy has been the standard of care for many years. In breast conserving surgery (BCS), maybe preferred in selected patient group[16,17]. In our study, in accordance with the literature, 2/3 patients had MRM and 14% SLND. BCS was applied to two patients.

In addition to cytopathology, immunohistochemical analyzes are used in the diagnosis of PD[10]. Oncoproteins, tumor suppressors, steroid hormone receptors, intermediate filaments, glycoproteins and other proteins are used for immunohistochemical analysis[7]. Immunohistochemistry, is useful in differential diagnosis of PD. Her2 is a transmembrane growth factor receptor protein. Its overexpression correlates with high grade tumors and poorer prognosis. Cyclin D1 is a nuclear protein associated with good prognosis. Bcl2 is an outer mitochondrial membrane protein associated with good prognosis. P53 is a tumor suppressor and its overexpression has been associated with poor prognosis. Cytokeratins are epithelial tissue proteins often found in glandular epithelium and expression in 98–100 % of PD cases. Vimentin is an intermediate filament protein its expression is associated with high tumor invasiveness and metastasis[7]. In our study, most of these analyzes were used for pathological diagnosis.

Approximately 80-90% of cases are associated with an underlying breast malignancy in the form of in situ ductal carcinoma (DCIS) or invasive breast cancer[9]. In our present study, invasive breast cancer accompanied PD in 91.8% of the patients. Although only PD was detected in 1 patient, DCIS was detected in 3 patients.

It will be related to the high frequency of palpable masses that our patients with lesions> 2 cm have a statistically significant higher LNI frequency ($p = 0.04$). However, none of the markers with positive staining properties detected by immunohistochemistry could not be found to be statistically significant with LNI ($p>0.05$). In addition, there was no statistically significant difference between female PD and male PD in terms of immunohistochemical positive staining ($p>0.05$).

Surveillance in PD patients was generally low (18). They attributed this to the fact that PD usually accompanies another underlying malignant breast tumor and the frequency of Her2 positivity[7]. In our study, while over 50 years of age were statistically significant (p: 0.012) as poor prognostic factors for PD, and although there was a difference in lesions diameter over 20 mm, this difference was not

©Copyright 2020 by Çukurova Anestezi ve Cerrahi Bilimler Dergisi - Available online at http://dergipark.gov.tr/jocass

statistically significant (p: 0.055). In addition, interestingly, unlike the literature, it was determined that patients with Her2 positivity status were better in surveillance and this difference was statistically significant (p: 0.002). This difference: we attribute the fact that our male patients, whom we know had a worse prognosis for breast cancer, were Her2 negative in our study.

Our study has some limitations. First of all, factors such as the fact that it is a retrospective study and that 23 patients do not follow-up in our center reduce the quality of our study, but the investigation of risk factors for PD in terms of surveillance is unique in that the number of male PD patients in our study is higher than similar studies in the literature.

Conclusion

In conclusion, although PD is rare, it is an important disease that should not be missed. Even if imaging methods do not detect any pathology in the breast, it is still seen that physical examination is very important in this disease. We think that the breast examination of the patients who apply to us with breast disease should definitely be done and the nipple should be evaluated carefully during the examination. In addition, it should be kept in mind that PD can also be seen in men. Although Her2 positivity is generally considered as a poor prognostic factor in breast cancers, we think that those with Her2 negativity may also have a poor prognosis in PD.

Conflict of Interest

The authors declare that they have no conflict of interest

Funding

None

References

1. Raivoherivony ZI, Feron J, Klijanienko J. The utility of nipple scraping in the diagnosis of Paget disease of the breast. Diagn Cytopathol. 2019 Mar;47(3):249-250. doi: 10.1002/dc.24033. Epub 2018 Nov 28. PMID: 30484956.
2. Lim HS, Jeong SJ, Lee JS, Park MH, Kim JW, Shin SS, Park JG, Kang HK. Paget disease of the breast: mammographic, US, and MR imaging findings with pathologic correlation. Radiographics. 2011 Nov-Dec;31(7):1973-87. doi: 10.1148/rg.317115070. PMID: 22084182.
3. Ikeda DM, Helvie MA, Frank TS, Chapel KL, Andersson IT. Paget disease of the nipple: radiologic-pathologic correlation. Radiology. 1993 Oct;189(1):89-94. doi: 10.1148/radiology.189.1.8396786. PMID: 8396786.
4. Sek P, Zawrocki A, Biernat W, Piekarski JH. HER2 molecular subtype is a dominant subtype of mammary Paget's cells. An immunohistochemical study. Histopathology. 2010 Oct;57(4):564-71. doi: 10.1111/j.1365-2559.2010.03665.x. Erratum in: Histopathology. 2010 Dec;57(6):944. PMID: 20955381.
5. Fu W, Mittel VK, Young SC. Paget disease of the breast: analysis of 41 patients. Am J Clin Oncol. 2001 Aug;24(4):397-400. doi: 10.1097/00000421-200108000-00019. PMID: 11474272.
6. Tanaka VD, Sanches JA, Torezan L, Niwa AB, Festa Neto C. Mammary and extramammary Paget's disease: a study of 14 cases and the associated therapeutic difficulties. Clinics (Sao Paulo). 2009;64(6):599-606. doi: 10.1590/s1807-59322009000600018. PMID: 19578667; PMCID: PMC2705154.
7. Sandoval-Leon AC, Drews-Elger K, Gomez-Fernandez CR, Yepes MM, Lippman ME. Paget's disease of the nipple. Breast Cancer Res Treat. 2013 Aug;141(1):1-12. doi: 10.1007/s10549-013-2661-4. Epub 2013 Aug 9. PMID: 23929251.
8. Challa VR, Deshmane V. Challenges in Diagnosis and Management of Paget's Disease of the Breast-a Retrospective Study. Indian J Surg. 2015 Dec;77(Suppl 3):1083-7. doi: 10.1007/s12262-014-1167-6. Epub 2014 Sep 18. PMID: 27011515; PMCID: PMC4775644.

©Copyright 2020 by Çukurova Anestezi ve Cerrahi Bilimler Dergisi - Available online at http://dergipark.gov.tr/jocass

9. Sripathi S, Ayachit A, Kadavigere R, Kumar S, Eleti A, Sraj A. Spectrum of Imaging Findings in Paget's Disease of the Breast-A Pictorial Review. Insights Imaging. 2015 Aug;6(4):419-29. doi: 10.1007/s13244-015-0415-z. Epub 2015 Jul 5. PMID: 26142549; PMCID: PMC4519816.
10. Adams SJ, Kanthan R. Paget's disease of the male breast in the 21st century: A systematic review. Breast. 2016 Oct;29:14-23. doi: 10.1016/j.breast.2016.06.015. Epub 2016 Jul 6. PMID: 27394005.
11. Lohsiriwat V, Martella S, Rietjens M, Botteri E, Rotmensz N, Mastropasqua MG, Garusi C, De Lorenzi F, Manconi A, Sommario M, Barbieri B, Cassilha M, Minotti I, Petit JY. Paget's disease as a local recurrence after nipple-sparing mastectomy: clinical presentation, treatment, outcome, and risk factor analysis. Ann Surg Oncol. 2012 Jun;19(6):1850-5. doi: 10.1245/s10434-012-2226-5. Epub 2012 Feb 10. PMID: 22322949.
12. Kanwar AJ, De D, Vaiphei K, Bhatia A, Sharma RK, Singh G. Extensive mammary Paget's disease. Clin Exp Dermatol. 2007 May;32(3):326-7. doi: 10.1111/j.1365-2230.2006.02326.x. PMID: 17397359.
13. Nicoletti G, Scevola S, Ruggiero R, Coghi AM, Toussoun GS. Gigantic Paget disease of the breast. Breast. 2004 Oct;13(5):425-7. doi: 10.1016/j.breast.2003.11.005. PMID: 15454200.
14. Ucar AE, Korukluoglu B, Ergul E, Aydin R, Kusdemir A. Bilateral Paget disease of the male nipple: first report. Breast. 2008 Jun;17(3):317-8. doi: 10.1016/j.breast.2007.11.007. Epub 2008 Jan 2. PMID: 18171616.
15. Yen PP, Sinha N, Barnes PJ, Butt R, Iles S. Benign and Malignant Male Breast Diseases: Radiologic and Pathologic Correlation. Can Assoc Radiol J. 2015 Aug;66(3):198-207. doi: 10.1016/j.carj.2015.01.002. Epub 2015 Jun 12. PMID: 26073217.
16. Dominici LS, Lester S, Liao GS, Guo L, Specht M, Smith BL, Golshan M. Current surgical approach to Paget's disease. Am J Surg. 2012 Jul;204(1):18-22. doi: 10.1016/j.amjsurg.2011.07.010. Epub 2011 Oct 28. PMID: 22036205.
17. Marshall JK, Griffith KA, Haffty BG, Solin LJ, Vicini FA, McCormick B, Wazer DE, Recht A, Pierce LJ. Conservative management of Paget disease of the breast with radiotherapy: 10- and 15-year results. Cancer. 2003 May 1;97(9):2142-9. doi: 10.1002/cncr.11337. PMID: 12712465.
18. Ortiz-Pagan S, Cunto-Amesty G, Narayan S, Crawford S, Derrick C, Larkin A, Khan A, Quinlan R, Layeequr Rahman R. Effect of Paget's disease on survival in breast cancer: an exploratory study. Arch Surg. 2011 Nov;146(11):1267-70. doi: 10.1001/archsurg.2011.278. PMID: 22106318.

©Copyright 2020 by Çukurova Anestezi ve Cerrahi Bilimler Dergisi - Available online at http://dergipark.gov.tr/jocass