JoCASS
Çukurova Anestezi ve Cerrahi Bilimler Dergisi
2018 Adana

COMPARISON OF PREECLAMPTIC AND NORMAL PLACENTAS WITH HISTOPATHOLOGICAL AND CLINICAL FINDINGS

PREEKLAMPTİK VE NORMAL PLASENTALARIN HİSTOPATOLOJİK VE KLİNİK BULGULAR EŞLİĞİNDE KARŞILAŞTIRILMASI

Ethem Ömeroğlu[1], Zeynep Bayramoğlu[1], Ayşe Nur Uğur Kılınç[1], Oğuzhan Günenç[2], Elif Nur Yıldırım Öztürk [3], Yaşar Ünlü[1]

1 Department of Pathology, Konya Training and Research Hospital, Turkey
2 Department of Gynecology and Obstetrics, Konya Training and Research Hospital, Turkey
3 Department of County Health, Konya Akşehir, Turkey

Sorumlu Yazar/Corresponding Author: Zeynep Bayramoğlu E-mail: drzeynepbayramoglu@hotmail.com
Geliş Tarihi/Received: 25.09.2020 Kabul Tarihi-Accepted: 02.11.2020 Available Online Date/Çevrimiçi Yayın Tarihi: 09.11.2020
Cite this article as: Ömeroğlu E, Bayramoğlu Z, Kılınç ANU, Günenç O, Öztürk ENY, Ünlü Y. Comparison of Preeclamptic and Normal Placentas with Histopathological and Clinical Findings. J Cukurova Anesth Surg. 2020;3(3):142-54. *Doi:* 10.36516/jocass.2021.50
0000-0002-4943-6871,0000-0001-7075-8819,0000-0002-0439-010,0000-0003-4373-5245, 0000-0003-1447-9756,0000-0002-3951-8881

Abstract

Introduction: Preeclampsia (PE) is one of the most important reasons leading to maternal, and neonate morbidity and mortality. The pathophysiology of PE has yet to be fully elucidated. Hypoperfusion, hypoxia and ischemia are the critical components in the etiopathogenesis of PE. Here, we aimed to investigate the association between chronic villitis, infarction, edema, calcification, chorangiosis, perivillous fibrin deposits, fibrosis in villi, syncytial knot increase, retroplacental detachment, average placental weight, age, gravity, parity, abortion, hemoglobin, platelet, lactate dehydrogenase (LDH), D-dimer and protein 24 levels, and the clinical results.

Materials and Methods: With no significant differences in age, gravity, abortion and parity values, 91 pregnant women diagnosed with PE in the preeclamptic placentae in our pathology department between 2015 and 2018, and 92 normal healthy pregnant women were included as the study and the control groups. Patients and babies' data were obtained from their files, and the laboratory data were obtained from the hospital automation records. Hematoxylin and eosin-stained preparations of the placentae were removed and re-evaluated from the archive. The data were analyzed by number, percentage, mean, standard deviation, and correlation tests. Numeric variables were investigated by *t* test in independent groups while categorical data were assessed by chi-square test. Results with $p<0.05$ were considered statistically significant.

Results: As to age, gravity, parity, abortion, hemoglobin, platelet, LDH, D-dimer and protein 24 levels, no statistical difference was found between the study and control groups ($p>0.05$). Mean placental weight was 330.8±89 g and 431±59 g in the study and control groups. Retroplacental detachment was 7% in six cases (6/85) in the study group, while 1% in one case (1/92) in the controls. Mean gestational weeks were found as 33±3 and 38±1 weeks in the study and control groups. No statistically significant association was determined between the study and control groups for gravity, abortion, chorangiosis, villitis, edema, chorioamnionitis, calcification, perivillous fibrin and syncytial knot increase ($p>0.05$).

Conclusion: Based on our findings, there were some differences in placental histopathology of preeclamptic patients; the differences may be related to placental insufficiency. However, the absence of differences in various placental histopathological parameters also supports that every perinatal problem is not associated with a placental abnormality, nor is every placental pathology associated with a perinatal malfunction.

Keywords: Chorangiosis, hypoxia, placenta, preeclampsia, retroplacental detachment

©Copyright 2020 by Çukurova Anestezi ve Cerrahi Bilimler Dergisi - Available online at http://dergipark.gov.tr/jocass

Öz
Giriş: Preeklampsi (PE) maternal ve neonat morbidite ve mortalitenin en önemli nedenleri arasında yer alan bir hastalıktır. PE'nin patofizyolojisi tam olarak aydınlatılamamıştır. Hipoperfüzyon, hipoksi ve iskemi PE'nin etiyopatogenezinde kritik bileşenlerdir. Bu çalışmanın amacı PE'li ve sağlıklı gebelerin plesantalarındaki kronik villitis, infarkt, ödem, kalsifikasyon, korangiozis, perivillöz fibrin depoziti, villüslerde fibrozis, sinsityal knot artışı, retroplasental dekolman, plasental ağırlık ortalaması, yaş, gravite, parite, abortus, hemoglobin, platelet, LDH, D-Dimer ve Protein 24 düzeyleri ile klinik sonuçlarının incelenmesidir.
Gereç ve Yöntemler: Çalışmamızda 2015-2018 yılları arasında patoloji bölümümüze tanı almış yaş, gravite, abortus, parite değerlerinde anlamlı farklılık bulunmayan preeklamptik ve kontrol grubu gebe plasentalarında 91 PE tanılı gebe ve kontrol grubu olarak ise 92 normal sağlıklı gebe alındı. Hastaların ve bebeklerin verileri dosyalarından, laboratuvar verileri hastane otomasyon sisteminden elde edildi. Plasentaya ait hematoksilen ve eozin boyalı preperatlar arşivden çıkarılarak tekrar değerlendirildi. Veriler sayı, yüzde, ortalama, standart sapma, korelasyon testleri ile analiz edildi. Sayısal değişkenler arası ilişkiler bağımsız gruplarda t testi ile ve kategorik veriler arası ilişkiler Ki-kare testi ile araştırılmıştır. P<0,05 olan test sonuçları, istatistiksel açıdan anlamlı kabul edilmiştir.
Bulgular: Yaş, gravite, parite, abortus, hemoglobin, platelet, LDH, D-Dimer ve protein 24 düzeyleri vaka ve kontrol grupları arasında istatistiksel olarak farklı bulunmadı (p>0,05). Çalışma grubunda plasental ağırlık ortalaması 330,8±89g iken kontrol grubunda plasental ağırlık ortalaması 431±59g bulunmuştur. Retroplasental dekolman ise çalışma grubunda 6 olguda 7% (6/85) oranında bulunmuşken kontrol grubunda 1 olguda 1% (1/92) oranında izlenmiştir. Analiz ettiğimiz olgularda gebelik haftaları ortalamaları çalışma grubu hastalarında 33±3, kontrol grubu olgularında ise 38±1 bulunmuştur. Gravite, abortus, korangiozis, villitis, ödem, korioamnionit, kalsifikasyon, perivillöz fibrin ve sinsityal knot artışı için vaka ve kontrol grupları arasında istatistiksel olarak anlamlı ilişki belirlenmedi (p>0,05).
Sonuç: Bulgularımıza göre preklamptik hastalarda plasental histopatolojide bazı parametrelerde farklılıklar mevcuttur bu farklılıklar plasental yetmezlik ile ilişkili olabilir. Ancak bir kısım plasental histopatolojik parametrelerde de farklılık olmaması her perinatal sorunun plasental bir anormallikle ilişkili olmadığı gibi her plasental patolojinin de perinatal kötü sonuçla ilişkili olmadığını desteklemektedir.

Anahtar Kelimeler: Preeklampsi, koranjiozis, plasenta, retroplasental dekolman, hipoksi

Introduction

Constituting between 5-6% of all pregnancies worldwide, preeclampsia (PE) is a multisystemic complex syndrome, specific to pregnancy, progressing with high blood pressure (BP) and associated with serious mortality and morbidity[1]. PE ranks among the first three causes of maternal mortality across the world[2]. In order to diagnose PE in a pregnant woman who was previously normotensive, the most significant parameter is high BP usually occurring after 20 gestational weeks. As well as high BP, such disorders as proteinuria, thrombocytopenia, an increase in liver function tests, impaired renal function, visual symptoms, pulmonary edema, severe headache and pain in the epigastric region may be witnessed in preeclamptic patients[3].

The etiopathogenesis of PE has yet to be fully understood. In recent studies, PE has been suggested to be multifactorial and associated with abnormal remodeling in spiral arteries, defect of trophoblast differentiation, hypoperfusion, hypoxia, ischemia, immunological causes, genetic and environmental factors, increased sensitivity to angiotensin-II, inflammation and cytokines[4]. Although their role cannot fully be understood in PE, extravillous trophoblasts (EVT) are seen as a culprit in the invasion into the myometrial part of the spiral arteries[5]. Due to the insufficient EVT invasion in the myometrium, arterial integrity is impaired, and therefore the decrease in perfusion leads to the placental hypoperfusion,

©Copyright 2020 by Çukurova Anestezi ve Cerrahi Bilimler Dergisi - Available online at http://dergipark.gov.tr/jocass

hypoxia, ischemia, and tissue damage[6]. Systemic findings are also considered to occur through the maternal inflammatory mediators as a result of the increase in oxidative stress[7,8]. Along with ischemia developing due to hypoperfusion in the placenta, such challenges as atherosis, fibrinoid necrosis, thrombosis, sclerotic narrowing of arterioles and placental infarction can be encountered[9,10]. In addition, chorangiosis may also be seen in the preeclamptic placenta due to chronic hypoxia[11].

In our department, standard evaluations were performed macroscopically for all placentae. First, the shape of the placenta, its color, location of the umbilical cord and color of the placental membranes were investigated, and all samples were also examined in terms of retroplacental hematoma. Then the umbilical cord was separated. The placenta was measured three-dimensionally, and the vertical slices of placentae were taken at 1 cm intervals. The samples were obtained from the umbilical cord, fetal membranes, and parenchyma. All patients in our study were re-assessed for chronic villitis, infarction, villous edema, calcification, chorangiosis, perivillous fibrin deposits, fibrosis in villi and syncytial knot increase.

In conclusion, we aimed here to re-evaluate such factors as age, gravity, parity, abortion, hemoglobin, platelet, LDH, D-dimer and protein 24 levels, chronic villitis, infarction, villous edema, calcification, chorangiosis, perivillous fibrin deposits and the increases of fibrosis in villi and syncytial knots in the placentae of the pregnant women with PE and normal healthy controls in our hospital in light of literature.

Materials and Methods

With no significant differences in age, gravity, abortion, and parity values, 91 pregnant women diagnosed with PE in the preeclamptic placentae in our pathology department between 2015 and 2018, and 92 normal healthy pregnant women were included as the study and the control groups. Patients and babies' data were obtained from their files, and the laboratory data were obtained from the hospital automation records. Patients with an additional comorbidity to preeclampsia were not included in the study. Hematoxylin and eosin-stained preparations of the placentae were removed and re-evaluated from the archive. The data were analyzed by number, percentage, mean, standard deviation, and correlation tests. Numeric variables were investigated by *t* test in independent groups whiler categorical data were assessed by chi-square test. Results with $p<0.05$ were considered statistically significant.

On histopathological examination, chorangiosis, villitis, edema, calcification, perivillous fibrin accumulation, increase in syncytial knotes and villous fibrins were evaluated as presence or absence. Necrosis was evaluated as absent, present ≤25% and present>25%. Statistical Analysis (through the Statistical Package of Social Sciences for Windows, version 22.0 (SPSS Inc., Chicago, IL, USA). The data entry and analyses were carried out in the computer environment through the Statistical Package of Social Sciences for Windows, version 22.0 (SPSS Inc., Chicago, IL, USA). Average, standard deviation (SD), median, minimum, and maximum values were used to summarize the numerical data, and the numbers and percentages were utilized to summarize the categorical data. The relationships between numerical variables were investigated by the *t* test in independent groups, while the relationships between categorical data were determined by the chi-square test. The test results with a value of $p<0.05$ were considered statistically significant.

©Copyright 2020 by Çukurova Anestezi ve Cerrahi Bilimler Dergisi - Available online at http://dergipark.gov.tr/jocass

Results

1. *Descriptive Statistics*

1.1. *Descriptives related to numerical variables (Table1, Table2, Table 3)*

Table 1. The numerical descriptive data for the whole research group

Variables	Mean	SD	Median	Minimum	Maximum
Age (years)	30	6	29	17	46
Gravity	3	2	3	0	12
Parity	2	1	2	0	8
Abortion	0	1	0	0	6
Pulse rate	85	11	83	64	114
Systolic BP	143	31	140	90	220
Diastolic BP	88	23	80	50	120
Hemoglobin	12.12	1.67	12.20	7.40	17.00
Platelet	222	74	220	43	549
Urea	21	10	18	7	63
Creatinine	0.68	0.17	0.64	0.43	1.70
Fetal Weight (gr)	2440	938	2640	350	4350
1-Min. Apgar Score	6	3	8	0	10
Number of Used Antihypertensive Drug	1	1	0	0	3

BP: Blood pressure, SD: Standard deviation

Table 2. The numerical descriptive data for the study group

Variables	Mean	SD	Median	Minimum	Maximum
Age (years)	30	6	30	17	44
Gravity	3	2	3	0	7
Parity	2	1	2	0	6
Abortion	0	1	0	0	4
Pulse rate	88	11	89	64	114
Systolic BP	171	16	170	130	220
Diastolic BP	109	8	110	90	120
Hemoglobin	12.31	1.74	12.40	8.40	17.00

©Copyright 2020 by Çukurova Anestezi ve Cerrahi Bilimler Dergisi - Available online at http://dergipark.gov.tr/jocass

Platelet	217	84	216	43	549
Urea	24	11	22	7	63
Creatinine	0.75	0.21	0.70	0.43	1.70
Fetal Weight (gr)	1752	778	1720	350	4330
1-Min. Apgar Score	5	3	5	0	9
Number of Used Antihypertensive Drug	2	1	2	0	3

BP: Blood pressure, SD: Standard deviation

Table 3. The numerical descriptive data for the control group

Variables	Mean	SD	Median	Minimum	Maximum
Age (years)	30	6	29	18	46
Gravity	3	2	3	1	12
Parity	2	2	2	0	8
Abortion	0	1	0	0	6
Pulse rate	82	9	82	64	108
Systolic BP	116	12	120	90	150
Diastolic BP	66	8	60	50	80
Hemoglobin	11.93	1.58	12.10	7.40	15.20
Platelet	227	64	224	88	439
Urea	17	5	16	7	40
Creatinine	0.61	0.08	0.61	0.45	0.85
Fetal Weight (gr)	3121	466	3138	2200	4350
1-Min. Apgar Score	8	1	8	6	10
Number of Used Antihypertensive Drug	0	0	0	0	0

BP: Blood pressure, SD: Standard deviation

©Copyright 2020 by Çukurova Anestezi ve Cerrahi Bilimler Dergisi - Available online at http://dergipark.gov.tr/jocass

1.2. *Descriptive related to categorical variables*

Of the study participants consisting of a total of 183 women, 49.7% (n=91) consisted of preeclamptic patients as the study group, while and 50.3% (n=92) were composed of those with normal pregnancy as the controls.(Table 4)

Table 4. Descriptive data related to categorical variables

Variables		Study Participants (n=183)		Study Group (n=91)		Control Group (n=92)	
		n	%	n	%	n	%
Gravity	**No**	1	0.5	1	1.1	0	0.0
	Yes	182	99.5	90	98.9	92	100.0
Parity	**No**	41	22.4	27	29.7	14	15.2
	Yes	142	77.6	64	70.3	78	84.8
Abortion	**No**	136	74.3	67	73.6	69	75.0
	Yes	47	25.7	24	26.4	23	25.0
Urea	**Negative**	77	42.3	1	1.1	76	82.6
	1+	62	34.1	46	51.1	16	17.4
	2+	3	1.6	3	3.3	0	0.0
	3+	40	22.0	40	44.4	0	0.0
Umbilical Doppler USG	**Normal**	138	75.4	46	50.5	92	100.0
	Impaired	29	15.8	29	31.9	0	0.0
	No	16	8.7	16	17.6	0	0.0
Intrauterine Exitus	**No**	164	89.6	72	79.1	92	100.0
	Yes	19	10.4	19	20.9	0	0.0
MgSO4	**Administered**	86	47.0	86	94.5	0	0.0
	Not administered	97	53.0	5	5.5	92	100.0
Antihypertensive drug	**Not used**	93	51.1	2	2.2	91	100.0
	Used	89	48.9	89	97.8	0	0.0
Chorangiosis	**No**	157	93.5	77	93.9	80	93
	Yes	11	6.5	5	6.1	6	7
Villitis	**No**	166	98.8	80	97.6	86	100.0
	Yes	2	1.2	2	2.4	0	0.0
Edema	**Yok**	15	8.9	15	18.3	0	0.0
	Var	49	29.2	23	28.0	26	30.2
Necrosis	**No**	33	19.6	17	20.7	16	18.6
	Yes, ≤25%	120	71.4	50	61.0	70	81.4
	Yes, >25%	15	8.9	15	18.3	0	0.0
Calcification	**No**	98	58.3	47	57.3	51	59.3
	Yes	70	41.7	35	42.7	35	40.7
Perivillous fibrin accumulation	**No**	2	1.2	1	1.2	1	1.2
	Yes	166	98.8	81	98.8	85	98.8
Increase of syncytial knots	**No**	131	78.0	59	72.0	72	83.7
	Yes	37	22.0	23	28.0	14	16.3
Villous fibrins	**No**	111	66.1	43	52.4	68	79.1
	Yes	57	33.9	39	47.6	18	20.9

MgSO4: Magnesium sulphate, USG: Ultrasonography

©Copyright 2020 by Çukurova Anestezi ve Cerrahi Bilimler Dergisi - Available online at http://dergipark.gov.tr/jocass

2. Comparisons between the study and control groups

2.1. The comparison of numerical variables through the *t* test in independent groups

No statistical difference was found between the study and control groups in terms of age, gravity, parity, abortion, hemoglobin, platelets, LDH, D-dimer and protein 24 levels (p>0.05). While the mean placental weight was 330.8±89 g in the study group, the weight was detected as 431±59 g among the controls.

However, the retroplacental detachment was determined in 7% (6/85) of the patients in the study group, while the detachment was observed only in 1% (1/92) of the healthy controls. The mean gestational weeks in the subjects analyzed here were found as 33±3 weeks in the study group patients, while the mean number was detected as 38±1 weeks in the control group (Table 5).

Table 5. The comparison of numerical variables through the *t* test in independent groups

Variables	Group	n	Mean	SD	Statistics of *t* test	p
Pulse	Cases	91	88.04	11.192	4.309	0.001
	Controls	92	81.59	8.943		
Systolic BP	Cases	91	171.26	15.874	27.103	0.001
	Controls	92	115.76	11.506		
Diastolic BP	Cases	91	108.96	8.183	36.034	0.001
	Controls	92	66.41	7.786		
Urea	Cases	91	24.41	11.132	5.999	0.001
	Controls	92	16.65	5.336		
Creatinin	Cases	91	.7478	.21042	5.838	0.001
	Controls	92	.6102	.07959		
Fetal weight	Controls	14	584.36	206.604	-14.435	0.001
	Cases	91	1751.54	777.509		
	Controls	92	3121.30	466.054		
1-Min APGAR	Cases	91	4.62	2.843	-12.085	0.001
	Controls	92	8.35	0.777		
Number of Used Antihypertensive Drug	Cases	91	1.84	0.793	22.090	0.001
	Controls	91	0.00	0.000		

BP: Blood pressure, SD: Standard deviation

©Copyright 2020 by Çukurova Anestezi ve Cerrahi Bilimler Dergisi - Available online at http://dergipark.gov.tr/jocass

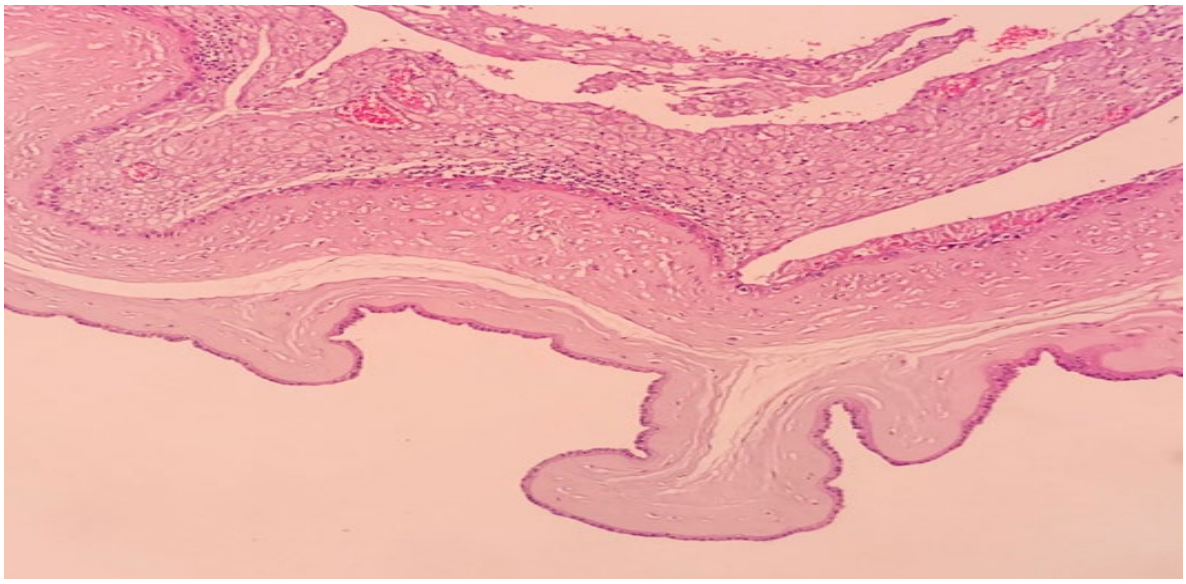

Figure 1: Chorioamnionitis on histopathological examination (H&E 100X)

2.2. The evaluation of categorical variables through the chi-square test (Table 6)

No statistically significant difference was observed between both groups in terms of gravity, abortion, chorangiosis, villitis, edema, chorioamnionitis (Figure-1), calcification (Figure-2), perivillous fibrin and increase in syncytial knots ($p>0.05$).

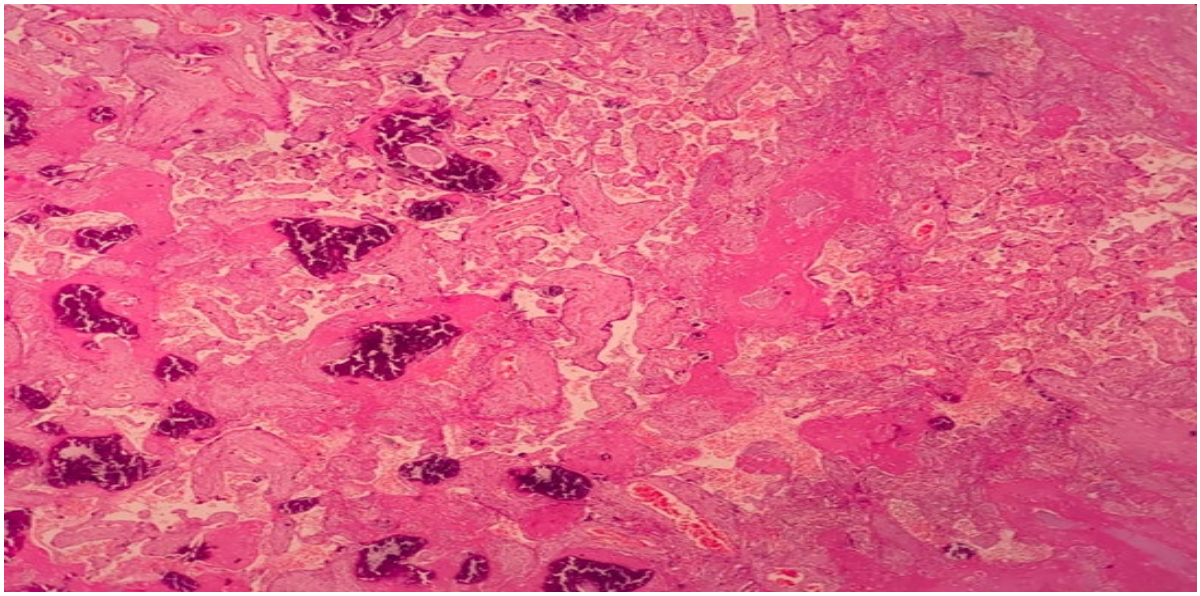

Figure 2: Calcification on histopathological examination (H&E 100X)

©Copyright 2020 by Çukurova Anestezi ve Cerrahi Bilimler Dergisi - Available online at http://dergipark.gov.tr/jocass

Table 6. The evaluation of categorical variables through the chi-square test

Variables		Study Group (n=91)		Control Group (n=92)		Chi-square Test	p
		n	%	n	%		
Parity	**No**	27	29.7	14	15.2	4.697	0.030
	Yes	64	70.3	78	84.8		
Urea	**Negative**	1	1.1	76	82.6	123.797	0.001
	Positive (+1. +2. +3)	89	98.9	16	17.4		
Umbilical Doppler USG	**Normal**	46	50.5	92	100.0	51.486	0.001
	Impaired	29	31.9	0	0.0		
	No	16	17.6	0	0.0		
Intrauterine Exitus	**No**	72	79.1	92	100.0	19.249	0.001
	Yes	19	20.9	0	0.0		
MgSO4	**Administered**	86	94.5	0	0.0	164.030	0.001
	Not administered	5	5.5	92	100.0		
Antihypertensive drug	**Not used**	2	2.2	91	100.0	174.172	0.001
	Used	89	97.8	0	0.0		
Necrosis	**No**	17	20.7	16	18.6	3.976	0.046
	Yes, ≤25%	50	61.0	70	81.4		
	Yes, >25%	15	18.3	0	0.0		
Villous fibrins	**No**	43	52.4	68	79.1	13.280	0.001
	Yes	39	47.6	18	20.9		

MgSO4: Magnesium sulphate, USG: Ultrasonography

Discussion

The infarction, necrosis and the increase developing due to the syncytial proliferation in the placentae of preeclamptic pregnant women were emphasized by various authors[12-14]. There was a significant difference only in the necrosis and villous fibrin, two of the histological parameters we investigated, between preeclamptic and control groups in our study; however, no difference was detected among other parameters, such as chronic villitis, edema, calcification, chorangiosis, perivillous fibrin deposits and the increase in syncytial knots. In a study including a series of 84 cases and performed by Chhatwal et al.[15] with hypertensive pregnant women, villous fibrin and necrosis were found to be higher in hypertensive pregnant women, as consistent with our findings; however, no difference was detected in terms of the increase of syncytial knots and calcification. Since many histological parameters were assessed, and a large sample were included, our study is important to shed light on future studies to

©Copyright 2020 by Çukurova Anestezi ve Cerrahi Bilimler Dergisi - Available online at http://dergipark.gov.tr/jocass

investigate similar entities.

Although calcification has frequently been observed in diabetes mellitus (DM) and Rhesus (Rh) incompatibility, the significance of maternal or fetal clinic has not been determined. In our study, the rate of calcification observed in histopathological placenta samples was found as 40%, and no difference was detected between the preeclamptic and control groups, as consistent with the findings reported in literature[15].

Unless the perivillous fibrin accumulation in the intervillous space exceeds 30-40% of the placental volume (i.e. massive perivillous fibrin accumulation), the accumulation causes no perinatal mortality or morbidity[16]. In our findings, no difference was found between the preeclamptic and control groups regarding the perivillous fibrin accumulation, as consistent with those in literature. Villous edema is seen in such disorders as DM, Rh incompatibility, preeclampsia and chorangioma, and in such infections as syphilis, toxoplasmosis and cytomegalovirus[17]. Based on our findings, edema was detected at a rate of 30%, and there was no significant difference between the two groups in terms of villous edema.

Chorangiosis can be defined as the presence of capillary hypervascularity in the placental terminal villi. However, chorangiosis is histologically diagnosed through the observation of 10 or more capillaries in each of 10 or more villi via the biopsies taken from three or more placental areas[18]. Chorangiosis is an uncommon placental histopathological finding considered to be associated with chronic hypoxia, and its prevalence is reported at approximately 5% in current literature. Since chorangiosis develops due to chronic hypoxia, the developmental process of structural changes probably occurs within weeks[19]. Since the development of chorangiosis lasts for weeks, the fetal morbidity cannot be attributed to the timing error or delay of the birth decision[20]. In our study, the rates of chorangiosis were found as 6.1% and 7% in the preeclamptic and control groups respectively, and no significant difference was witnessed between both groups in accordance with those reported in literature[18-20].

Syncytial knots have been defined as the presence of five or more clusters of trophoblastic nuclei. The presence of syncytial knots in more than one third of the villi is called the increase in syncytial knots. In studies conducted to investigate the increase of syncytial knots, an elevation was observed especially in the patients diagnosed with intrauterine growth retardation (IUGR) and preeclampsia. In a study where the placental pathologies of those with and without IUGR were compared by Iskender et al.[21], the increase in syncytial nodes was found to be significantly higher in the group with IUGR than those without IUGR[21]. In also another study in which the patients with severe preeclampsia were compared with the controls by Eren et al. an increase was detected in syncytial nodes; however, the increase was observed not to be statistically significant[22]. In the study where Ogge et al.[16] investigated the placental lesions in the early and late preeclampsia, the syncytial knots were found to be increased significantly as 56.8% in the study group and 26.7% in the control group ($p<0.001$). Even so, the increases in syncytial knots were determined to be 22% in the preeclamptic group and 16% in the control group in our study, and no statistically significant difference was found. In light of literature, in another recent study conducted by Chhatwal et al.[15], the increases in syncytial knots were found similar to our study findings, and there was also no significant

©Copyright 2020 by Çukurova Anestezi ve Cerrahi Bilimler Dergisi - Available online at http://dergipark.gov.tr/jocass

difference between the study and control groups[15].

Necrosis is one of the most easily monitored signs of maternal uteroplacental insufficiency and observed in 25% of normal or prolonged pregnancies. Based on our findings, the presence of necrosis over 25% was found to be significantly higher in the preeclamptic group, compared to the controls ($p<0.05$). The rates of necrosis in our study and control groups were consistent with those reported by Chattwal et al. in the hypertensive and control groups[15].

Hypertension and retroplacental hemorrhages have been associated in many studies in literature, and in one of those studies, the association between hypertension and retroplacental hemorrhages was stated as 10% in 30 pregnant women with moderate hypertension[23]. In our study, the area of retroplacental hematoma was present in six (7%) cases in the preeclamptic group, whereas the finding was present only in one (1%) patient in the control group. In our study, while the mean placental weight was observed as 330.8±89 g in the preeclampsia group, the mean weight was detected as 431±59 g in the control group. In literature, the placental weight was found to be 432 g at 38th week of gestation, that is, for the control group[24]. Even so, the placental weight was determined as 324 g at 32nd gestational week, accepted as the average gestational week in our preeclampsia group. Our findings are compatible with those reported in literature, and we consider that few changes occurred in the placental weight of preeclamptic patients.

In the preeclamptic group, postpartum urea and LDH levels were found to be significantly higher and thrombocyte levels significantly lower. These findings support previous studies showing that degradation products are increased as a result of widespread endothelial damage in preeclampsia, and as a result, there is a significant decrease in both platelet and fibrinogen levels. It was found that urea creatinine values increased as a result of a decrease in intravascular volume as a result of endothelial damage.

In our study, oligohydramnios, and impaired umbilical artery doppler findings were found to be increased in the pregnant group with preeclampsia. Intrauterine fetal death was observed in the preeclampsia group and there was no intrauterine fetal death in the control group. The rate of newborns with low APGAR scores in the pregnant group with preeclampsia was found to be significantly higher than the control group. As a result of impaired uteroplacental blood flow in preeclampsia, the decrease in the amount of amnion and disruption in fetal circulation, which has an important role in the evaluation of fetal well-being, is consistent with previous studies. Oligohydramnios may be one of the first findings to be detected as a result of impaired fetal circulation[25]. In the case of persistent circulatory disorder, the expected finding is fetal acidosis, and the low APGAR scores of newborn babies can be explained by the increase in admission to the neonatal intensive care unit and the prolonged stay in the circulatory system[25]. It should not be ignored that fetal weight affects both the low APGAR score and the prolongation of admission to the neonatal intensive care unit and the treatment process. If it cannot be intervened as a result of impaired uteroplacental blood flow, the expected final finding in the fetus is intrauterine death. The number of intrauterine deaths is high in the pregnant group with preeclampsia. It shows similar results to other studies in which disruption in uteroplacental blood flow in the pregnant group with preeclampsia is bad in terms of fetal outcomes[26].

©Copyright 2020 by Çukurova Anestezi ve Cerrahi Bilimler Dergisi - Available online at http://dergipark.gov.tr/jocass

Conclusion

Based on our study findings, there were several differences in the placental histopathology of preeclamptic patients as to some parameters, and these differences may have arisen from the placental insufficiency. However, the absence of differences in some placental histopathological parameters also supports the notion that every perinatal problem is not associated with a placental abnormality, nor is every placental pathology is associated with a perinatal malfunction. We consider that since many histological parameters were assessed, and a large sampling was included, our study is important in terms of shedding light on similar future studies.

Conflict of Interest

The authors declare that they have no conflict of interest

Funding

None

References

1. Henderson JT, Thompson JH, Burda BU, Cantor A, Beil T, Whitlock EP. Screening for preeclampsia: a systematic evidence review for the US Preventive Services Task Force. 2017 https://doi.org/10.1001/jama.2016.18315.
2. Brown, H. L., & Small, M. J. (2014). Overview of Maternal mortality & morbidity. Pub Med.
3. Woelkers D, Barton J, von Dadelszen P, Sibai B. [71-OR]: the revised 2013 ACOG definitions of hypertensive disorders of pregnancy significantly increase the diagnostic prevalence of preeclampsia. Pregnancy Hypertension: An International Journal of Women's Cardiovascular Health. 2015;5(1):38.
4. Laresgoiti-Servitje E. A leading role for the immune system in the pathophysiology of preeclampsia. J Leukoc Biol. 2013 Aug;94(2):247–57.
5. Jauniaux E, Watson AL, Hempstock J, Bao YP, Skepper JN, Burton GJ. Onset of maternal arterial blood flow and placental oxidative stress. A possible factor in human early pregnancy failure. Am J Pathol. 2000 Dec;157(6):2111–22.
6. Burton GJ, Hung TH. Hypoxia-reoxygenation; a potential source of placental oxidative stress in normal pregnancy and preeclampsia. Fetal Matern Med Rev. 2003;14(2):97–117.
7. Chen A, Li C, Wang J, Sha H, Piao S, Liu S. Role of toll-like receptor 3 gene polymorphisms in preeclampsia. Cell Physiol Biochem. 2015;37(5):1927–33.
8. Myatt L, Roberts JM. Preeclampsia: syndrome or Disease? Curr Hypertens Rep. 2015 Nov;17(11):83.
9. Harmon AC, Cornelius DC, Amaral LM, Faulkner JL, Cunningham MW Jr, Wallace K, et al. The role of inflammation in the pathology of preeclampsia. Clin Sci (Lond). 2016 Mar;130(6):409–19..
10. Nelson DB, Ziadie MS, McIntire DD, Rogers BB, Leveno KJ. Placental pathology suggesting that preeclampsia is more than one disease. Am J Obstet Gynecol. 2014 Jan;210(1):66.e1–7.
11. Suzuki K, Itoh H, Kimura S, Sugihara K, Yaguchi C, Kobayashi Y, et al. Chorangiosis and placental oxygenation. Congenit Anom (Kyoto). 2009 Jun;49(2):71–6.
12. Papageorghiou AT, Yu CK, Bindra R, Pandis G, Nicolaides KH; Fetal Medicine Foundation Second Trimester Screening Group. Multicenter screening for pre-eclampsia and fetal growth restriction by transvaginal uterine artery Doppler at 23 weeks of gestation. Ultrasound Obstet Gynecol. 2001 Nov;18(5):441–9.
13. Soma H, Yoshida K, Mukaida T, Tabuchi Y. Morphologic changes in the hypertensive placenta. Contrib Gynecol Obstet. 1982;9:58–75.
14. Choudhury M, Friedman JE. Epigenetics and microRNAs in preeclampsia. Clin Exp Hypertens. 2012;34(5):334–41.
15. Chhatwal J, Chaudhary DN, Chauhan N. Placental changes in hypertensive pregnancy: a comparison with normotensive pregnancy. Int J Reprod Contracept Obstet Gynecol. 2018 Aug;7(9):3809.
16. Ogge G, Chaiworapongsa T, Romero R, Hussein Y, Kusanovic JP, Yeo L, et al. Placental lesions associated with maternal underperfusion are more frequent in early-onset than in late-onset

©Copyright 2020 by Çukurova Anestezi ve Cerrahi Bilimler Dergisi - Available online at http://dergipark.gov.tr/jocass

preeclampsia. J Perinat Med. 2011 Nov;39(6):641–52.
17. Kaplan C, Lowell D. Salafia CJAop, medicine l. College of American Pathologists Conference XIX on the examination of the placenta: report of the working group on the definition of structural changes associated with abnormal function in the maternal/fetal/placental unit in the second and third trimesters. 1991;115(7):709.
18. Altshuler G. Chorangiosis. An important placental sign of neonatal morbidity and mortality. Arch Pathol Lab Med. 1984 Jan;108(1):71–4.
19. Ogino S, Redline RW. Villous capillary lesions of the placenta: distinctions between chorangioma, chorangiomatosis, and chorangiosis. Hum Pathol. 2000 Aug;31(8):945–54.
20. Sevinç A. (2016). Plasentasyon bozukluğu ile birlikte olan gebeliklerde plasentanın histopatolojik incelenmesi. Tez, Eskişehir
21. İskender-Mazman D, Akçören Z, Yiğit Ş, Kale G, Korkmaz A, Yurdakök M, et al. Placental findings of IUGR and non-IUGR. Turk J Pediatr. 2014 Jul-Aug;56(4):368–73.
22. Eren S, Kuyumcuoğlu U, Aydoğmuş H, Okay İ, Alkan A, Ertekin K. Preeklamptik Ve Normal Gebelerde Plasentanin Işik Ve Elektron Mikroskobu İle İncelenmesi.
23. Ahmed M, Daver RG. Study of placental changes in pregnancy induced hypertension. Int J Reprod Contracept Obstet Gynecol. 2013;2(4):524–7.
24. Baergen RN. Manual of Benirschke and Kaufmann's pathology of the human placenta. Springer Science & Business Media; 2005.
25. Schwarze A, Nelles I, Krapp M, Friedrich M, Schmidt W, Diedrich K, et al. Doppler ultrasound of the uterine artery in the prediction of severe complications during low-risk pregnancies. Arch Gynecol Obstet. 2005 Jan;271(1):46–52.
26. American College of Obstetricians and Gynecologists; Task Force on Hypertension in Pregnancy. Hypertension in pregnancy. Report of the American College of Obstetricians and Gynecologists' task force on hypertension in pregnancy. Obstet Gynecol. 2013 Nov;122(5):1122–31.

©Copyright 2020 by Çukurova Anestezi ve Cerrahi Bilimler Dergisi - Available online at http://dergipark.gov.tr/jocass