JoCASS
Çukurova Anestezi ve Cerrahi Bilimler Dergisi
2018 Adana

# CAN FIBULIN-5 INDUCE GASTROINTESTINAL STROMAL TUMOR DEVELOPMENT?

## FİBULİN-5 GASTROİNTESTİNAL STROMAL TÜMÖR GELİŞİMİNİ İNDÜKLEYEBİLİR Mİ?

Meryem İlkay Eren Karanis[1], Hande Köksal[2]

*1 Sağlık Bilimleri Üniversitesi Konya Eğitim ve Araştırma Hastanesi Patoloji Kliniği, Konya, Türkiye*
*2 Sağlık Bilimleri Üniversitesi Konya Eğitim ve Araştırma Hastanesi Genel Cerrahi Kliniği, Konya, Türkiye*

*Sorumlu Yazar/Corresponding Author: Meryem İlkay Eren Karanis E-mail: dr-ilkay@hotmail.com*
*Geliş Tarihi/Received: 02.10.2020 Kabul Tarihi-Accepted: 14.12.2020 Available Online Date/Çevrimiçi Yayın Tarihi: 31.12.2020*
*Cite this article as: Karanis MİE, Köksal H.* Can Fibulin-5 Induce Gastrointestinal Stromal Tumor Development?
J Cukurova Anesth Surg. 2020;3(3):275-85. *Doi:* 10.36516/jocass.2021.65
*0000-0002-1097-4592, 0000-0002-9668-7913*

Abstract

Objective: Gastrointestinal stromal tumors are the most common primary mesenchymal tumors of the gastrointestinal tract and show Cajal cell differentiation. Fibulin-5 is a multifunctional extracellular matrix protein that inhibits epithelial and endothelial cell proliferation. Expression of fibulin-5 is down-regulated in various carcinomas. In contrast, fibulin-5 stimulates fibroblast and fibrosarcoma cells. In this study we aimed to investigate the expression of fibulin-5 in Cajal cells and gastrointestinal stromal tumors.

Materials and Methods: Immunohistochemical fibulin-5 staining is performed on 34 (22 gastric and 12 small intestinal) gastrointestinal stromal tumors. Fibulin-5 staining intensity was scored in 4 quantitative categories and compared with clinicopathological features of the patients.

Results: There was no staining in 4 of the gastrointestinal stromal tumors; weak staining in 20 cases, moderate staining in 6 cases, and strong staining in 4 cases were observed. In 3 cases Cajal cells were detected with fibulin-5 by moderately staining. The relationship between fibulin-5 staining intensity and age and gender of the cases, localization, size, grade, and the risk groups of the tumors was not statistically significant.

Conclusion: A great proportion of gastrointestinal stromal tumors show fibulin-5 expression, even if weak, in contrast to the infrequent fibulin-5 expression in Cajal cells. Based on these findings, it can be speculated that the expression of fibulin-5 in Cajal cells can be increase cell proliferation, but it would be useful to conduct new studies with larger series to clarify this issue. There is no correlation between fibulin-5 expression intensity and clinicopathological and prognostic data of gastrointestinal stromal tumors.

Key Words; FBLN5, fibulin-5, gastrointestinal stromal tumor, GIST

©Copyright 2020 by Çukurova Anestezi ve Cerrahi Bilimler Dergisi - Available online at http://dergipark.gov.tr/jocass

Öz

Amaç: Gastrointestinal stromal tümörler, gastrointestinal sistemin en sık görülen primer mezenkimal tümörleridir ve Cajal hücre farklılaşması gösterir. Fibulin-5, epitelyal ve endotelyal hücre proliferasyonunu inhibe eden çok fonksiyonlu ekstraselüler bir matriks proteinidir. Fibulin-5 ekspresyonu çeşitli karsinomlarda aşağı regüle edilir. Buna karşılık, fibulin-5, fibroblast ve fibrosarkom hücrelerini uyarır. Bu çalışmada fibulin-5'in Cajal hücrelerinde ve gastrointestinal stromal tümörlerde ekspresyonunu araştırmayı amaçladık.

Materyal Metod: 34 (22 mide ve 12 ince bağırsak) gastrointestinal stromal tümöre immünohistokimyasal fibulin-5 boyası uygulandı. Fibulin-5 boyama yoğunluğu 4 kantitatif kategoride skorlandı ve hastaların klinikopatolojik özellikleri ile karşılaştırıldı.

Sonuçlar: Gastrointestinal stromal tümörlerin 4'ünde boyanma yoktu; 20 vakada zayıf, 6 vakada orta derecede ve 4 vakada kuvvetli boyanma gözlendi. 3 vakada orta derecede fibulin-5 boyanması ile Cajal hücreleri tespit edildi. Fibulin-5 boyanma yoğunluğu ile olguların yaş ve cinsiyeti; tümörlerin lokalizasyonu, boyutu, derecesi ve risk grupları arasındaki ilişki istatistiksel olarak anlamlı değildi.

Sonuç:Cajal hücrelerindeki seyrek fibulin-5 ekspresyonunun aksine, zayıf da olsa gastrointestinal stromal tümörlerin büyük bir kısmı fibulin-5 ekspresyonu gösterdi. Bu bulgulara dayanarak, Cajal hücrelerinde fibulin-5 ekspresyonunun hücre proliferasyonunu artırabileceği tahmin edilebilir ancak bu konuyu netleştirmek için daha geniş serilerle yeni çalışmalar yapmak faydalı olacaktır. Fibulin-5 ekspresyon yoğunluğu ile gastrointestinal stromal tümörlerin klinikopatolojik ve prognostik verileri arasında herhangi bir korelasyon yoktur.

Anahtar Kelimeler; FBLN5, fibulin-5, gastrointestinal stromal tümör, GIST

## Introduction

Gastrointestinal stromal tumors (GISTs) are the most common primary mesenchymal tumors of the gastrointestinal tract. Usually presenting during a patient's seventh decade, they are mostly observed in the stomach, and they show phenotypically Cajal cell differentiation[1]. Cajal cells are the pacemaker cells of the gastrointestinal tract and are thought to be specialized smooth muscle cells[2]. Although Cajal cells constitute only 5% of the tunica muscularis cells in the gastrointestinal tract, they have important physiological roles in gastrointestinal motility[3,4]. They have large oval nuclei, narrow cytoplasm, and dendritic-like extensions[5].

It is difficult to differentiate GISTs from other mesenchymal tumors only by morphological findings. Pathologic diagnosis of a GIST is based on both characteristic microscopic features and ancillary immunohistochemical techniques such as DOG-1, CD117, CD34, actin, desmin and S-100[1]. Tumor size, mitosis count and anatomical location are useful in risk classification. There are also studies showing that CD117, Ki67, and other immune markers in the antibody panel appear to be useful in risk classification[6]. The main morphologic types of GISTs are the spindle cell type, epithelioid cell type, and mixed type.

Fibulin-5 is secreted by various cell types, such as fibroblasts, vascular smooth muscle cells, and endothelial cells[7]. Fibulin-5 acts as a multifunctional extracellular matrix protein. It plays a role in organogenesis and vasculogenesis by mediating intercellular and cell-matrix communication throughout embryonic development and is involved in the stabilization of the basement membrane and loose connective tissue by regulating elastic fiber formation. Fibulin-5 also regulates tissue regeneration and repair in arterial and lung injuries. Besides these roles and functions, they are also known to affect tumorigenesis[8]. Fibulin-5 inhibits epithelial and endothelial cell proliferation, and expression of fibulin-5 is down-regulated in various carcinomas, especially in carcinomas of the breast, colon, ovary, and kidney[7,9,10]. In contrast,

©Copyright 2020 by Çukurova Anestezi ve Cerrahi Bilimler Dergisi - Available online at http://dergipark.gov.tr/jocass

fibulin-5 stimulates fibroblast and fibrosarcoma cells[11].

To the best of our knowledge, there are few studies researching the expression of fibulin-5 in human tumors, and these studies usually include carcinomas[7, 9-12]. There are very few studies in the literature on the expression of fibulin-5 in mesenchymal tumors[7].

In this study, we aimed to search fibulin-5 expression levels in Cajal cells and in GISTs immunohistochemically. We purposed to investigate whether fibulin-5 plays a role in GIST pathogenesis by comparing fibulin-5 staining intensity in Cajal cells and in GISTs. Moreover, we wanted to examine clinical importance of fibulin-5 in GISTs and search whether fibulin-5 could be a new prognostic parameter for GIST by analyzing the relationship between fibulin-5 expression intensity in GISTs and known prognostic factors of the GISTs.

## Materials and Methods

For this study, ethical approval was obtained from the Ethics Committee of Selcuk University, Faculty of Medicine (2018/320). The ethics committee decided that informed consent was not required because the study was a retrospective study.

A total of 34 patients (22 gastric GISTs and 12 small intestinal GISTs) who underwent subtotal gastrectomy or partial bowel resection and were diagnosed with GIST in the Konya Education and Research Hospital between 2010-2018 were included in the study. The clinical and pathological data of the cases, such as age, gender, tumor localization and tumor dimension were obtained from the patient files. Hematoxylin-Eosin and Ki67 stained preparations of the tumor specimens were re-evaluated by a pathologist, and histological type, mitosis count, grade and Ki67 proliferation index of the tumors were determined. Prognostic groups were determined according to tumor diameter and mitotic count (Table 1)[1].

**Table 1.** Risk groups of gastrointestinal stromal tumors according to United States Armed Forced Institute of Pathology

| Category | Mitotic rate (mitosis/5 mm²) | Tumor size (Cm) |
|---|---|---|
| 1 | ≤5 | ≤ 2 |
| 2 | | > 2 to ≤ 5 |
| 3a | | > 5 to ≤ 10 |
| 3b | | > 10 |
| 4 | >5 | ≤ 2 |
| 5 | | > 2 to ≤ 5 |
| 6a | | > 5 to ≤ 10 |
| 6b | | > 10 |

Sections of 4 µm thickness were prepared from the GISTs on polylysine slides. For immunohistochemical staining, fibulin-5 antibody for immunohistochemistry (UniProtKB, Inc, Q9UBX5 (FBLN5-HUMAN)) was used. The exhaustive protocol was attained from the datasheet of the product, and in accordance with the protocol, slides were stained with fibulin-5 (1/200 concentration) and then counterstained with Mayer hematoxylin by Leica Bond-Max fully automated IHC & ISH instrument. The stained preparations were then sealed with a coverslip using Entellan.

Finally, slides were evaluated under light microscope by an uncommitted pathologist. Only cytoplasmic staining was considered as positive staining. The results for fibulin-5 staining were scored in 4 quantitative categories according to the intensity of positively stained cells: score 0-negative; score 1-weak staining;

©Copyright 2020 by Çukurova Anestezi ve Cerrahi Bilimler Dergisi - Available online at http://dergipark.gov.tr/jocass

score 2-moderate staining; and score 3-strong staining.

The statistical analyses were performed using SPSS 22.0 for Windows (SPSS, Chicago, IL, USA). The Shapiro-Wilk test was used for examining the continuous variables with normal and non-normal distributions, while the one-way analysis of variance (ANOVA) was used for the normally distributed continuous variables. The Kruskal-Wallis test was used for the non-normally distributed continuous variables. When the Kruskal-Wallis test indicated statistically significant differences, the causes of those differences were determined using a Bonferroni-adjusted Mann-Whitney U test. Categorical data was analysed by Pearson's chi-square test, and Fisher's exact test was applied if the expected frequency was less than 5 in >20% of all cells. The continuous variables were presented as the mean ± standard deviation (SD) or median (min-max), and the categorical variables were presented as the number of cases and percentage. For all possible multiple comparisons, the Bonferroni-adjustment was performed to control the type I errors. Statistical significance was set at $p < 0.05$.

## Results

Of the 34 GISTs included in the study, 22 (64.7%) tumors originated from the stomach, and 12 (35.3%) tumors originated from the small intestine. The ages of the cases ranged from 37 to 87 years (median, 61.5 years). Twenty of 34 cases were immunohistochemically evaluated with Ki67, and the Ki67 proliferative index was found to be at least 1%, with the highest at 60% and the median at 3%. Clinicopathological characteristics of the patients with gastrointestinal stromal tumors were briefed in Table 2.

When fibulin-5 was scored according to the intensity of staining, there was no staining in 4 (11.8%) GISTs; weak staining was observed in 20 (58.8%) GISTs; moderate staining occurred in 6 (17.6%) GISTs; and strong staining was observed in 4 (11.8%) GISTs (Figure 1).

Of the 34 cases, 24 had muscularis propria in the fibulin-5-stained sections, and Cajal cells were investigated in these areas. In 21 (87.8%) cases, Cajal cells could not be identified by immunohistochemical FBLN5, whereas in 3 (12.5%) cases Cajal cells were stained with fibulin-5 (Figure 2). The immunohistochemical staining of fibulin-5 in Cajal cells and GISTs is shown in Table 3. There was a statistically significant difference between GIST and Cajal cell in terms of fibulin-5 staining positivity ($p<0.001$).

Fibulin-5 staining intensities in GISTs were compared to the gender of the cases, tumor localization, histological type of the tumors, tumor size, mitotic count, tumor grade due to mitotic rates and the risk groups determined according to mitotic rates and tumor dimensions. The relationship between fibulin-5 expression and clinical and pathological characteristics of gastrointestinal stromal tumors is shown in Table 4. The association between fibulin-5 staining intensities and clinical and pathological features of GISTs was not statistically significant ($p>0.05$).

©Copyright 2020 by Çukurova Anestezi ve Cerrahi Bilimler Dergisi - Available online at http://dergipark.gov.tr/jocass

**Table 2.** Clinicopathological characteristics of the patients with gastrointestinal stromal tumors

| **Characteristics** | | **Median** | **Min-Max** |
|---|---|---|---|
| **Age (years)** | | 61.50 | 37-87 |
| **Ki67 prolifaration index (%)** | | 3 | 1-60 |
| | | **Number (n)** | **Percentage (%)** |
| **Gender** | **Male** | 21 | 61.8 |
| | **Female** | 13 | 38.2 |
| **Tumor localisation** | **Stomach** | 22 | 64.7 |
| | **Duodenum** | 12 | 35.3 |
| **Histological type** | **Spindle** | 23 | 67.7 |
| | **Epithelioid** | 10 | 29.4 |
| | **Mixt (spindle+epithelioid)** | 1 | 2.9 |
| **Tumor size (cm)** | **≤ 2** | 2 | 5.9 |
| | **> 2 to ≤ 5** | 11 | 32.3 |
| | **> 5 to ≤ 10** | 14 | 41.2 |
| | **> 10** | 7 | 20.6 |
| **Mitotic count (/50 HPF)** | **≤ 5** | 25 | 73.5 |
| | **6-10** | 1 | 3.0 |
| | **> 10** | 8 | 23.5 |
| **Grade** | **Low mitotic rate** | 26 | 76.5 |
| | **High mitotic rate** | 8 | 23.5 |
| **Risk groups** | **1** | 2 | 5.9 |
| | **2** | 11 | 32.4 |
| | **3a** | 9 | 26.5 |
| | **3b** | 3 | 8.8 |
| | **6a** | 6 | 17.6 |
| | **6b** | 3 | 8.8 |

©Copyright 2020 by Çukurova Anestezi ve Cerrahi Bilimler Dergisi - Available online at http://dergipark.gov.tr/jocass

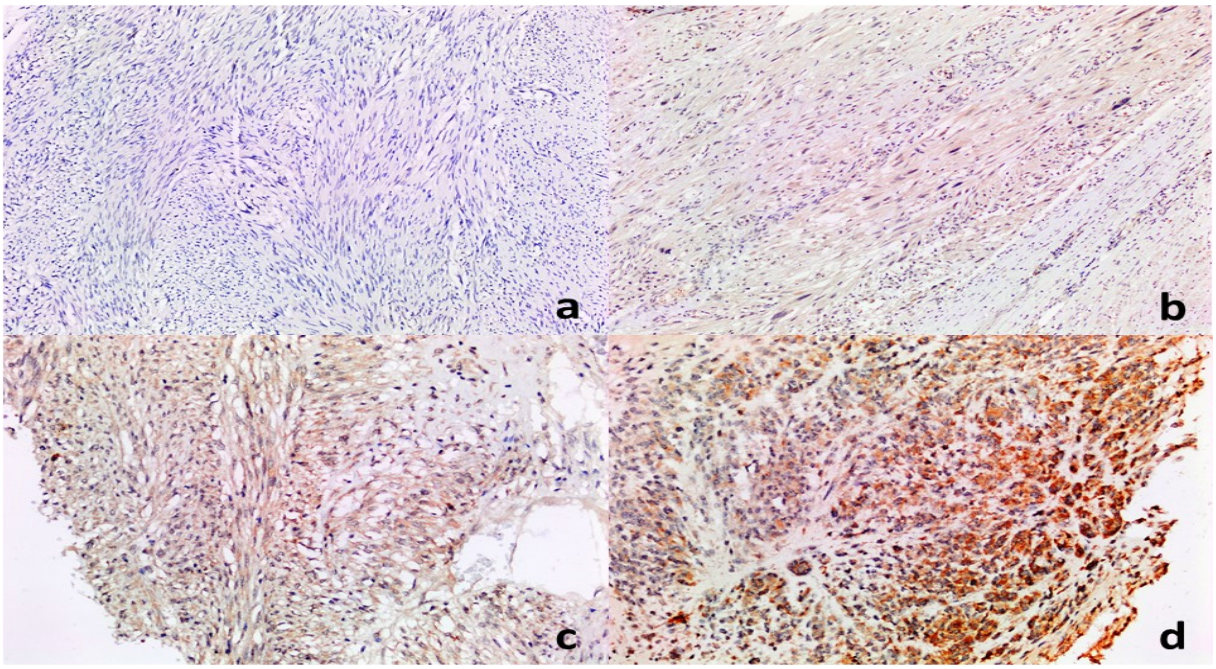


**Figure 1.** Staining scores with immunohistochemical fibulin-5 in GIST: a-score 0 (negative) Fibulin-5x100; b-score 1 (weak) Fibulin-5x200; c-score 2 (moderate) Fibulin-5x200; d-Score 3 (strong) Fibulin-5x200

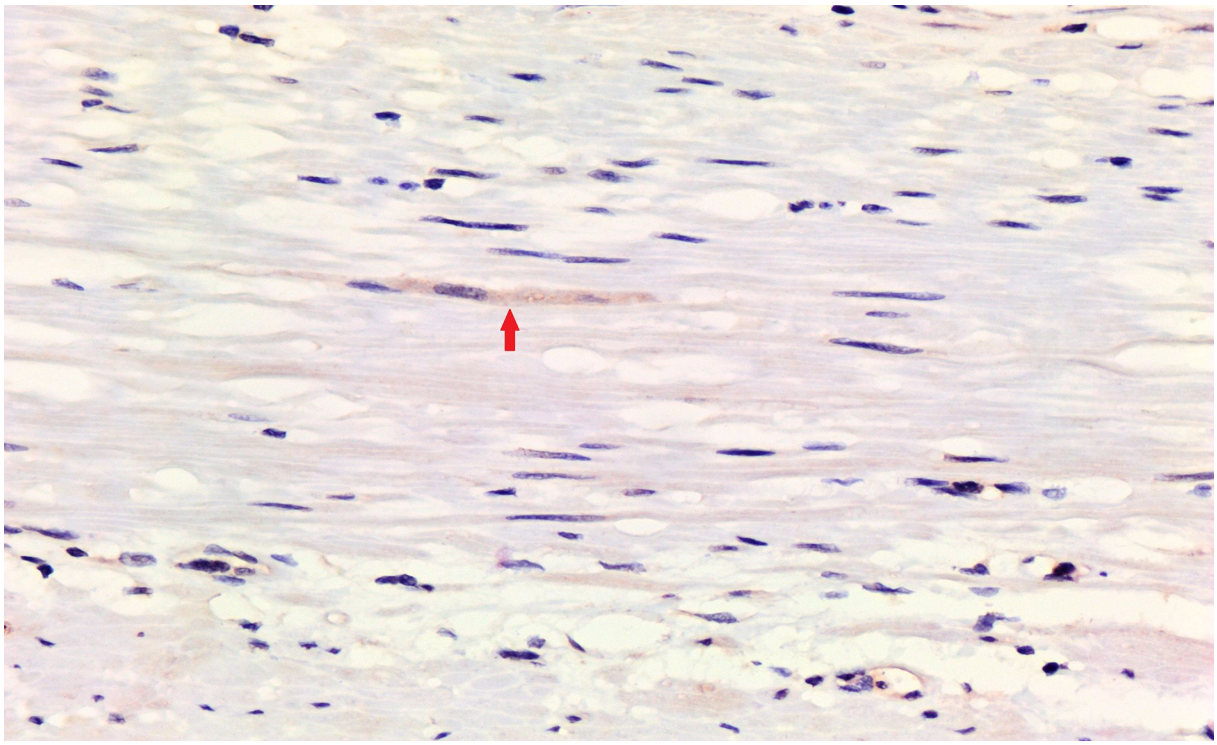

**Figure 2.** Moderate staining with immunohistochemical fibulin-5 in Cajal cell. FBLN5x400

©Copyright 2020 by Çukurova Anestezi ve Cerrahi Bilimler Dergisi - Available online at http://dergipark.gov.tr/jocass

**Table 3.** Immunohistochemical staining of fibulin-5 in Cajal cells and gastrointestinal stromal tumors

| **Immunohistochemical staining of FBLN5** | **Negative** | **Positive** | **p value** |
|---|---|---|---|
| Cajal cells (n=24) (%) | 21 (87.5) | 3 (12.5) | <0.001 |
| GIST (n=34) (%) | 4 (11.8) | 30 (88.2) | |

**Table 4.** Relationship between fibulin-5 expression and clinical and pathological characteristics of gastrointestinal stromal tumors

| **Fibulin-5 staining skor in GIST** | | **0 (n=4)** | **1 (n=20)** | **2 (n=6)** | **3 (n=4)** | **p value** |
|---|---|---|---|---|---|---|
| **Age (years)** | **Mean** | 61.75±11.33 | 60.95±12.23 | 60.50±14.58 | 65.75±8.54 | 0.903 |
| **Gender** | **Female** | 3 | 4 | 3 | 3 | 0.052 |
| | **Male** | 1 | 16 | 3 | 1 | |
| **Localisation** | **Stomach** | 1 | 15 | 3 | 3 | 0.217 |
| | **Small intestine** | 3 | 5 | 3 | 1 | |
| **Histological type** | **Spindlecell** | 4 | 15 | 4 | 0 | 0.019 |
| | **Epithelioid** | 0 | 5 | 2 | 3 | |
| | **Mixt** | 0 | 0 | 0 | 1 | |
| **Tumour size (cm)** | **≤ 2** | 1 | 1 | 0 | 0 | 0.373 |
| | **> 2 to ≤ 5** | 1 | 7 | 1 | 2 | |
| | **> 5 to ≤ 10** | 0 | 10 | 3 | 1 | |
| | **> 10** | 2 | 2 | 2 | 1 | |
| **Mitotic count (/50 HPF)** | **≤ 5** | 4 | 15 | 3 | 3 | 0.626 |
| | **6-10** | 0 | 1 | 0 | 0 | |
| | **> 10** | 0 | 4 | 3 | 1 | |
| **Grade** | **Low mitotic rate** | 4 | 16 | 3 | 3 | 0.294 |
| | **High mitotic rate** | 0 | 4 | 3 | 1 | |
| **Risk groups** | **1** | 1 | 1 | 0 | 0 | 0.174 |
| | **2** | 1 | 7 | 1 | 2 | |
| | **3a** | 0 | 7 | 1 | 1 | |
| | **3b** | 2 | 0 | 1 | 0 | |
| | **6a** | 0 | 3 | 2 | 0 | |
| | **6b** | 0 | 2 | 1 | 1 | |
| **Ki67 proliferation index (%)** | | **(n=2)** | **(n=14)** | **(n=2)** | **(n=2)** | 0.155 |
| | **< 5** | 0 | 11 | 1 | 1 | |
| | **≥ 5** | 2 | 3 | 1 | 1 | |

©Copyright 2020 by Çukurova Anestezi ve Cerrahi Bilimler Dergisi - Available online at http://dergipark.gov.tr/jocass

## Discussion

Fibulin-5 is an ECM protein that participates in the setting and stabilization of basal membranes, elastic fibers and loose connective tissue interacts with various extracellular matrix proteins such as tropoelastin, fibrillin, elastin microfibril interface 1, lysyl oxidase-like 1, or apolipoprotein[8]. Fibulin-5 provides intercellular and cell-matrix communication in embryonic development and organogenesis. It also plays a role in angiogenesis and epithelial-mesenchymal transition[9]. Besides these structural and developmental functions, studies to date have shown that fibulin-5 is effective in tumorigenesis[7].

The expression of fibulin-5 is stimulated by transforming growth factor-β, which is a tumor suppressor[10]. It acts on tumor formation and progression by influencing cell proliferation control, angiogenic sprouting, and oncogenic epithelial-mesenchymal transition[7]. Fibulin-5 has a reducing effect on endothelial and epithelial cell proliferation[10,12]. Compared to corresponding normal tissue, the expression of fibulin-5 is significantly reduced in many human tumors (such as breast, ovary, colon, and kidney), and associated with this condition the concentration of fibulin-5 in the tumor microenvironment suppresses tumor growth and progression[10]. Mohamedi et al.[13] revealed that fibulin-5 down-regulates Ki-67, inhibiting proliferation and invasion of breast cancer cells, and thus breast cancer patients with a high level of fibulin-5 demonstrate better outcomes. Yue et al.[14] found that epigenetic ineffectiveness of fibulin-5 increases the expansion of lung cancer.

In contrast to the effect of reducing proliferation in epithelial and endothelial cells, fibulin-5 enhances cell proliferation in fibroblast and fibrosarcoma cells by stimulating DNA synthesis and motility[7]. Based on the knowledge that fibulin-5 enhances cell proliferation in fibroblasts, which are mesenchymal cells, we sought to determine whether fibulin-5 expression is present in Cajal cells (also mesenchymal cells) and in GISTs, tumors that sometimes show Cajal cell differentiation.

We evaluated muscularis propria in 24 cases, and in only 3 of these 24 (12.5%) cases were we able to demonstrate Cajal cells with fibulin-5. On the other hand, we observed fibulin-5 expression in 30 of 34 GIST (88.2%) cases, with variable intensity. Fibulin-5 expression was clearly higher in the GISTs than in Cajal cells; however, the expression of fibulin-5 in GISTs was weak in most cases. GISTs show fibulin-5 expression, even if weak, in a greater proportion than do Cajal cells, which show infrequent fibulin-5 expression. From this evidence, it appears that the expression of fibulin-5 in Cajal cells increases cell proliferation like fibroblast and fibrosarcoma cells.

Tumor diameter and mitotic count are the most important parameters for predicting prognosis in GISTs. Risk groups determined according to tumor diameter and mitotic count are important guides for predicting disease progression. Tumors localized in the small intestine of the same risk group show more rapid progression than those localized in the stomach. This shows us that localization of the tumor is an important criteria that determine prognosis in GIST beside the tumor size and mitotic count. GISTs are graded by the mitotic rate[1].

Ki67 proliferative index has been reported to be an important predictive factor and associated with malignancy risk in GISTs[15,16]. Cerski et al.[17] suggested that the Ki67 proliferation index > 3% is an important parameter in demonstrating poor prognosis. On the other hand,

©Copyright 2020 by Çukurova Anestezi ve Cerrahi Bilimler Dergisi - Available online at http://dergipark.gov.tr/jocass

Basilio-de-Oliveira et al.[18] argued that Ki 67 proliferative index ≥ 5 % is closely related with poor prognosis. Although there are different opinions about the cut off value of Ki67 proliferation index, the authors agree that the prognosis is poor in patients with a high Ki67 proliferation index. JIAN et al.[19] reported that the expression of protein interacting with never in mitosis A1 (PIN1) as well as Ki67 proliferative index are associated with the prognosis of GIST. They suggested that both Ki67 and PIN1 may be potential prognostic indicator of GIST and PIN1 may be a therapeutic target for GIST. It is suggested that angiogenic markers such as CD105, CD31 and VEGF may be prognostic parameters for GIST[18]. It is asserted that unfavorable prognosis in GIST may occur from overexpression of BMI-1 mRNA and protein and BMI-1 mRNA and protein levels which can be used as prognostic predictor and a novel therapeutic target[20]. High blood fibrinogen level, gastrointestinal bleeding and tumor necrosis were associated with poor prognosis in GIST[21-23]. The relationship between exon 11 mutations, p16INK4A and prognosis of GIST were investigated and no association was determined[17].

Mohamedi et al.[13] revealed that fibulin-5 down-regulates Ki-67, inhibits proliferation and invasion of breast cancer cells, and thus breast cancer patients with a high level of fibulin-5 demonstrate better outcomes. Yue et al.[14] found that epigenetic ineffectiveness of fibulin-5 increases the expansion of lung cancer.

The prognostic assessment of GIST is a multifaceted issue indicating a complex multiparametric approach and it remains a matter of curiosity by the researchers. In this study, we aimed to reveal the expression and its prognostic value of fibulin-5, which plays a role in tumorigenesis and angiogenesis and affects the prognosis of tumors, in the GIST that is the most common mesenchimal tumor of the gastrointestinal tract.

When the intensity of fibulin-5 in GISTs is compared to clinical data such as gender; to pathological data such as tumor localization and histological type of tumor; and to prognostic parameters such as mitotic count, tumor grade, tumor diameter, and risk group, Ki 67 proliferative index no statistically significant relationship is detected between them ($p>0.05$). However, there are some limitations in our study. The number of cases in this series is limited and the long-term follow-up and treatment responses of our cases are unknown. Although the number of patients is small, there is a statistically significant relationship between the histological type of the tumor and fibulin-5 staining intensity. Epithelioid type GISTs exhibit stronger staining than spindle cell type GIST. Epithelioid type GISTs are known to be associated with poor prognosis[24]. However, it is difficult to say that strong fibulin-5 staining is associated with poor prognosis in GIST with this finding alone. Because no correlation was found between fibulin-5 staining and all other parameters closely related to prognosis in GISTs.

According to our knowledge our study is the first study with fibulin-5 in human mesenchymal tumors and additionally in GISTs. We observed fibulin-5 expression in 30 of 34 GIST cases. However, fibulin-5 staining in GIST was weak in most cases. GISTs frequently express varying degrees of fibulin-5, while fibulin-5 expression is rare in Cajal cells. This situation brings to mind the question "Can fibulin 5 induce GIST development?". However, the limitation of the number of cases and the weakness of staining prevent us to clearly state the fibulin-5 function in GIST pathogenesis. It would be useful to conduct new studies with larger series to clarify this issue. Although GISTs frequently express varying degrees of

©Copyright 2020 by Çukurova Anestezi ve Cerrahi Bilimler Dergisi - Available online at http://dergipark.gov.tr/jocass

fibulin-5, there is no correlation between fibulin-5 expression intensity and clinical, pathological, and prognostic data of GISTs.

## Conclusions

Further studies are required to elucidate this issue.

## Conflict of Interest

The authors declare that they have no conflict of interest

## Funding

None

## References


1. Fukayama M, Goldblum JR, Miettinen M, et al. Mesenchymal tumours of the digestive system. In WHO Classification of Tumours Editorial Board, editors. Digestive system Tumours. 5th ed:439-444. Lyon, IARC Press, 2019.
2. Sanders KM, Koh SD, Ward SM. Interstitial cells of Cajal as pacemakers in the gastrointestinal tract. Annu Rev Physiol. 2006;68:307-343. PMID: 16460275 DOI: 10.1146/annurev.physiol.68.040504.094718
3. Ördög T, Redelman D, Horváth VJ, et al. Quantitative analysis by flowcytometry of interstitial cells of Cajal, pacemakers, and mediators of neurotransmission in the gastrointestinal tract. Cytometry Part A: The Journal of the International Society for Analytical Cytology. 2004;62(2):139-149. PMID: 15536638 DOI: 10.1002/cyto.a.20078
4. Sanders KM, Ward SM. Kit mutants and gastrointestinal physiology. The Journal of physiology. 2007;578(1):33-42. PMID: 17095561 DOI: 10.1113/jphysiol.2006.122473
5. Mostafa RM, Moustafa YM, Hamdy H. Interstitial cells of Cajal, the Maestro in health and disease. World journal of gastroenterology: WJG. 2010;16(26):3239. PMID: 20614479 DOI: 10.3748/wjg.v16.i26.3239
6. Bülbül GD. Gastrointestinal stromal tumors: A multicenter study of 1160 Turkish cases. The Turkish journal of gastroenterology: the official journal of Turkish Society of Gastroenterology. 2012;23(3):203-211. PMID: 22798108
7. Albig AR, Schiemann WP. Fibulin-5 function during tumorigenesis. Future Oncol. 2005 Feb;1(1):23-35. PMID: 16555973 DOI: 10.1517/14796694.1.1.23
8. Mohamedi Y, Fontanil T, Solares L, et al. Fibulin-5 downregulates Ki-67 and inhibits proliferation and invasion of breast cancer cells. Int J Oncol. 2016 Apr;48(4):1447-56. PMID: 26891749 doi: 10.3892/ijo.2016.3394.
9. Lee YH, Albig AR, Regner M, et al. Fibulin-5 initiates epithelial-mesenchymal transition (EMT) and enhances EMT induced by TGF-beta in mammary epithelial cells via a MMP dependent mechanism. Carcinogenesis. 2008;29:2243–2251. PMID: 18713838 doi: 10.1093/carcin/bgn199
10. Guadall A, Orriols M, Rodríguez-Calvo R, et al. Fibulin-5 is up-regulated by hypoxia in endothelial cells through a hypoxia-inducible factor-1 (HIF-1alpha)-dependent mechanism. J BiolChem. 2011; 286:7093–7103. PMID:21193390 doi: 10.1074/jbc.M110.162917
11. Schiemann WP, Blobe GC, Kalume DE, et al. Context-specific effects of fibulin-5 (DANCE/EVEC) on cell proliferation, motility, and invasion. Fibulin-5 is induced by transforming growth factor-beta and affects protein kinase cascades. J BiolChem. 2002 Jul 26;277(30):27367-77. PMID: 12021267 DOI: 10.1074/jbc.M200148200
12. Yanagisawa H, Schluterman MK, Brekken RA. Fibulin-5, an integrin-binding matricellular protein: its function in development and disease. Journal of cell communication and signaling. 2009;3(3-4), 337-347.
13. Albig AR, Schiemann WP. Fibulin-5 antagonizes vascular endothelial growth factor (VEGF) signaling and angiogenic sprouting by endothelial cells. DNA and cell biology. 2004; 23(6): 367-379. PMID: 15231070 DOI: 10.1089/104454904323145254
14. Argraves WS, Greene LM, Cooley MA, et al. Fibulins: physiological and disease perspectives. EMBO Rep. 2003 Dec;4(12):1127-31. PMID: 14647206 DOI: 10.1038/sj.embor.7400033
15. Yue W, Sun Q, Landreneau R, et al. Fibulin-5 suppresses lung cancer invasion by inhibiting matrix metalloproteinase-7 expression. Cancer research. 2009; 69(15): 6339-6346. PMID: 19584278 DOI: 10.1158/0008-5472.CAN-09-0398
16. Li H, Ren G, Cai R, et al. A correlation research of Ki67 index, CT features, and risk stratification in gastrointestinal stromal tumor. Cancer medicine. 2018;7(9), 4467-4474.
17. Zhou Y, Hu W, Chen P, et al. Ki67 is a biological marker of malignant risk of gastrointestinal

stromal tumors: a systematic review and meta-analysis. Medicine. 2017;96(34).
18. Cerski MR, Pereira F, Matte US, et al. Exon 11 mutations, Ki67, and p16INK4A as predictors of prognosis in patients with GIST. Pathology-Research and Practice. 2011;207(11), 701-706.
19. Basilio-de-Oliveira RP, Pannain VLN. Prognostic angiogenic markers (endoglin, VEGF, CD31) and tumor cell proliferation (Ki67) for gastrointestinal stromal tumors. World Journal of Gastroenterology: WJG. 2015;21(22), 6924.
20. Jiang L, Cao M, Hu J, et al. Expression of PIN1 in Gastrointestinal Stromal Tumours and its Clinical Significance. Anticancer research. 2016;36(3), 1275-1280.
21. Zhu K, Li K, Yuan DW, et al. Clinicopathological and Prognostic Significance of Expression of B-Cell-Specific Moloney Murine Leukemia Virus Insertion Site 1 (BMI-1) Gene and Protein in Gastrointestinal Stromal Tumors. Medical science monitor: international medical journal of experimental and clinical research. 2018;24, 6414.
22. Lu J, Chen S, Li X, et al. Gastrointestinal stromal tumors: Fibrinogen levels are associated with prognosis of patients as blood-based biomarker. Medicine. 2018;97(17).
23. Liu Q, Li Y, Dong M, et al. Gastrointestinal bleeding is an independent risk factor for poor prognosis in GIST patients. BioMed research international. 2017;2017.
24. Yi M, Xia L, Zhou Y, et al. Prognostic value of tumor necrosis in gastrointestinal stromal tumor: A meta-analysis. Medicine. 2019;98(17).
25. Haller F, Cortis J, Helfrich J, et al. Epithelioid/mixed phenotype in gastrointestinal stromal tumors with KIT mutation from the stomach is associated with accelerated passage of late phases of the cell cycle and shorter disease-free survival. Modern Pathology. 2011;24(2), 248-255.

©Copyright 2020 by Çukurova Anestezi ve Cerrahi Bilimler Dergisi - Available online at http://dergipark.gov.tr/jocass