Case report
Olgu sunumu

INTENSE BUT CLINICALLY TRANSIENT CARBON MONOXIDE INTOXICATION WITH CHARACTERISTIC COMPUTED BRAIN TOMOGRAPHY IMAGES

YOĞUN FAKAT KLİNİK OLARAK GEÇİCİ KARBONMONOKSİT İNTOKSİKASYONU VE KARAKTERİSTİK BİLGİSAYARLI BEYİN TOMOGRAFİ GÖRÜNTÜLERİ

Süreyya TALAY[1], Emre Can MERMİ[1], Levent ENVER[1]

0000-0002-4908-3850, 0000-0002-0020-3110, 0000-0002-5873-3704
[1] 29 Mayıs Devlet Hastanesi Kalp ve Damar Cerrahisi Kliniği, Ankara, Türkiye
Sorumlu Yazar/Corresponding Author: Süreyya TALAY *E-mail: suereyyatalay@gmail.com*
Geliş Tarihi/Received: 12.12.2019 Kabul Tarihi-Accepted: 24.12.2019 Available Online Date/Çevrimiçi Yayın Tarihi: 18.03.2020
Cite this article as: Talay S, Mermi EC, Enver L. Intense but Clinically Transient Carbon Monoxide Intoxication with Characteristic Computed Brain Tomography Images. J Cukurova Anesth Surg. 2020:3(1),13-7. Doi:10.36516/jocass.2020.25

Öz

53 yaşında kadın hasta bilinç kaybı ile acil servisimize başvurdu. Hastanın iki saat kadar önce yüksekten düşme öyküsü mevcut idi. Hasta yakınları düşmeden önce evde baca temizliği yapıldığını ifade etmişlerdi. Hasta bilinçsiz olarak bulunmuş idi. Klinik değerlendirmemize uygun olarak hastanın nörolojik tablosunu açıklamak için 4 faklı dönemde beyin bilgisayarlı tomografi (BT) tetkiki yaptık. Intrakraniyal parenkimal ödem ve kanama olduğunu gördük. Radyoloji konsültasyonu, bu ödemin lokalizasyonunun ve karakteristiğinin karbon monoksit (CO) intoksikasyonuna spesifik olduğunu bildirdi. Sonuç olarak inanmaktayız ki, CO intoksikasyonundan şüphelenilmesi ve bu doğrultuda detaylı değerlendirme yaşam kurtarıcıdır. Kardiyak monitörizasyon, entübasyon ve %100 O2 uygulamaları, ayrıntılı fizik muayene ve radyolojik değerlendirme zorunludur. Seri beyin BT tetkikleri CO intoksikasyonuna ait aydınlatıcı ve spesifik bulgular verebilir.

Anahtar Kelimeler: Karbon monoksit intoksikasyonu, bilgisayarlı beyin tomogarfisi, geçici nörolojik bozulma

Abstract

53-year-old female patient was admitted to our emergency department with a loss of consciousness. The patient had a history of fall from height about two hours earlier. Relatives of the patients said they had been cleaning the chimney at the house before the fall. She was found unconsciousness. By our clinical algorithm, we performed cranial computed tomography (CT) to clarify patient's neurologic status in 4 different stages of our clinical follow-up. We observed parenchymal edema and intracranial hemorrhage. Localization and characteristics of this edema was reported to be specific to carbon monoxide (CO) intoxication. As a result, we state that a suspicion of CO intoxicity with a detailed evaluation is lifesaving. Cardiac monitoring, intubation and 100% oxygen applications, elaborate physical and radiological evaluations are mandatory. Serial CT scan of the brain can also present specific and enlightening findings in CO intoxicity cases.

Keywords:Carbon monoxide intoxication, cranial computed tomography, transient neurological dysfunction

©Copyright 2019 by Çukurova Anestezi ve Cerrahi Bilimler Dergisi - Available online at http://dergipark.gov.tr/jocass

Introduction

We report a case of an intense but clinically transient carbon monoxide exposure with pathognomonic radiological findings on sequential cranial computed tomography scans from a trauma patient.

Case Report

A female patient administered to our hospital with loss of consciousness. Her relatives explained that there is a possibility for her cleaning up her chimney of the house. She was found unconsciousness. The patient was resuscitated and intubated in another clinic. In our primary physical examination, we observed her vital signs as a sinus rhythm (100/min) and 170/90 arterial blood pressure. Her medical report which was achieved by her relatives was uneventful. Her calculated body mass index was 37,9 kg/m^2. In our initial neurological system evaluation revealed a seriously decreased neurologic status with a Glasgow Coma Scale in 5/15. She presented a shallow and irregular spontaneous respiration through her intubation tube. Her pupil examination showed a normal morphology in shape. However, her pupils were slightly dilated in size. Both pupils were both constrictive to light on both direct and indirect response with a mild and slower pattern. She also has acral cyanosis on both sides. Her lungs and heart were clear to auscultation. There was no active bleeding. The remainder of our examination was in normal limits. Thus, patient was transferred to our intensive care unit.

By our clinical algorithm, we performed cranial computed tomography (CT) to clarify patient's neurologic status and physical examination presentations in 3 different stages of our clinical follow-up.

Initial cranial CT by administration (Figure 1) revealed that there was not an obvious chance in density. However, evidences of bilateral brain edema and deterioration on gray-white matter margin were observable.

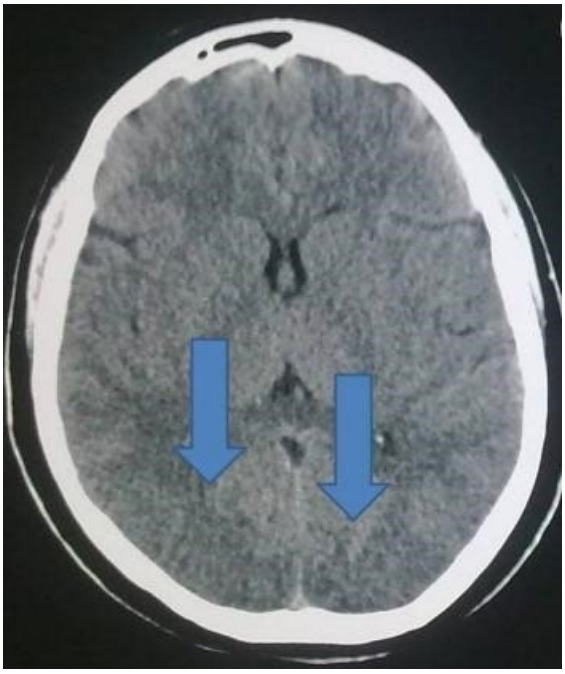

Figure 1. Initial cranial CT at administration, bilateral brain edema and detoriroration on gray-white matter margin.

Cranial CT at the 6th (Figure 2) showed that there were bilateral deep white-matter symmetrical diffuse density lowering. Besides, significant bilateral hiperdensity hemorrhage fields at globus pallidus areas were also fixed. Cranial CT at the 15th day (Figure 3) presented that there was an enhance on symmetrical density elevation.

©Copyright 2019 by Çukurova Anestezi ve Cerrahi Bilimler Dergisi - Available online at http://dergipark.gov.tr/jocass

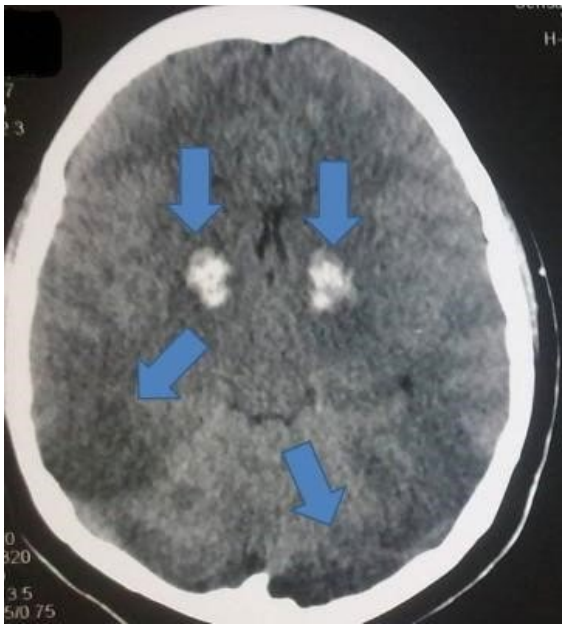

Figure 2. Cranial CT, day 6, bilateral deep white-matter symmetrical diffuse density lowering, bilateral hiperdensity hemorrhage fields at globus pallidus areas.

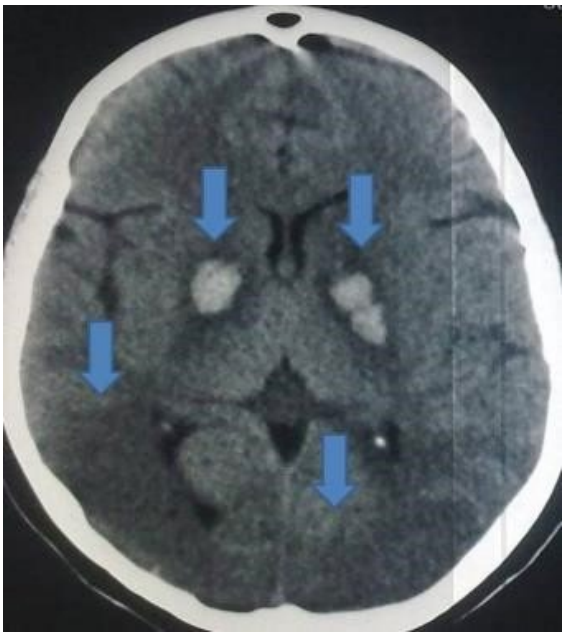

Figure 3. Cranial CT, day 15, enhance on symmetrical density elevation, edema around hemorrhage areas.

Furthermore, radiologist reported an edema around hemorrhage areas.

Our last cranial CT evaluation (Figure 4) took part at the end of a month (30th day). By this evaluation we depicted that hemorrhage areas were resorbed and bilateral deep white-matter lesions to continue as sequel changes. During this follow-up period, we treated patient's pulmonary infection with a combination of antibiotic medication for severe pneumonia which was complicated with a trachea-esophageal fistula (TEF). At the end of the first week we applied a tracheostomy cannula for both prolonged intubation and symptomatic TEF. By the end of the second week, patient presented a clinical and neurological improvement.

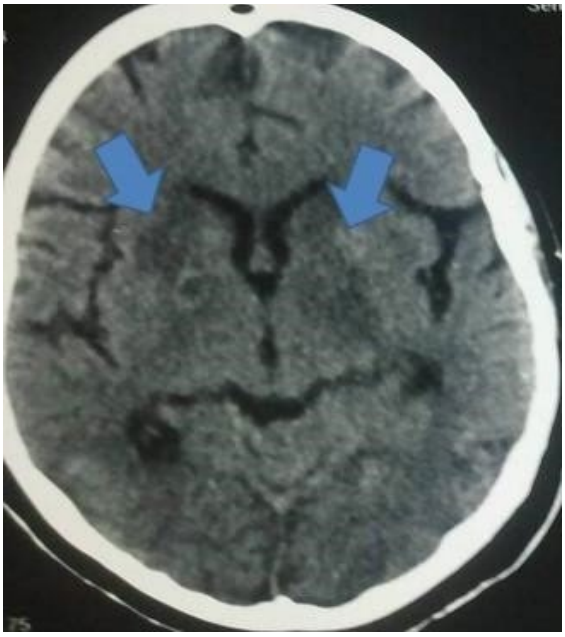

Figure 4. Cranial CT, day 30, bilateral deep white-matter lesions to continue as sequel changes.

©Copyright 2019 by Çukurova Anestezi ve Cerrahi Bilimler Dergisi - Available online at http://dergipark.gov.tr/jocass

However, presence of a TEF necessitated a corrective surgery. Thus, she was transferred to thoracic surgery department.

Discussion

CO is an odorless and colorless gas which is generally produced by fire, charcoal stoves and vehicle exhausts. Inhaling the gas around these sources result with CO intoxication with significant systemic effects of elevated CO levels. Individuals, as in our case, who use charcoal stoves seem to be at particularly risk for higher CO intoxication incidence. CO toxicity primarily depends on oxygen utilization, delivery and its extent of hemoglobin (Hb) affinity resulting with cellular hypoxia[1-3]. Even smaller amounts of CO inhalation may increase HbCO levels steadily. Thus, a life threatening relative functional anemia results with myocardial depression and hypotension. However, our patient was hypertensive and tachycardic due to her accompanying pathologies such as intracranial hemorrhage and severe pain with multiple soft tissue injuries which was probably caused by falling from a height.

Several studies present the effect of CO on central nervous system[4-6]. It is well indicated that CO differ the lipid peroxidation metabolism of the brain. Furthermore, a white matter demyelination, parenchymal edema and micro/macro necrosis. A posttraumatic cerebral change by direct trauma and/or contrecoup lesions in the brain also enhance neurological deterioration besides CO impacts, as in our case. Typical parenchymal lesions are generally reported to be at the localizations of globus pallidus[7,8]. However, our observation was mainly accumulated for occipital lobe with certain tomography findings of edema in our case. At this point, depending on the fact that an enhanced CO level up to 50-70% is a source of coma, an additive intraparenchymal hemorrhage can easily lead to fatality. Co-morbidities such as cardiovascular disease and chronic obstructive pulmonary disease certainly elevate the mortality rates of CO intoxication. Early symptoms of acute intoxication manifest fatigue, hallucination, confabulation, lethargy, impulsiveness, vomiting, headache, visual disturbances and seizures. These early clinical situations may rapidly advance to coma and death. Following recovery as in our case, several late symptoms by means of neuropsychiatric disturbances can be observed. But differential diagnoses play an important role at this period. It is essential and compulsatory to exclude meningitis, encephalitis, migraine-based headache, methemoglobinemia, alcohol/narcotics toxicity and hypoglycemia. These conditions may readily cast a suspicion on CO toxicity. Thus, laboratory studies from blood samples must be a component of routine evaluation for each case.

Cranial CT scans may not necessarily reflect the severity of CO intoxication especially for the initial phase. However, cerebral edema and focal/lobar lesions such as demyelination and hemorrhage predict a general need for further investigations. Almost half of the patients with neurological sequel which is caused by a possible CO intoxication may not present early brain CT scan result. An occipital lobe edema, as in our case, must

©Copyright 2019 by Çukurova Anestezi ve Cerrahi Bilimler Dergisi - Available online at http://dergipark.gov.tr/jocass

alert attending physician for a CO toxicity (9,10). At this early stages of evaluation, magnetic resonance images are reported to be more accurate than CT scans for demyelination's. By our experience, brain images may present significant differences in sequential scans during the patient's follow up. Thus, it is suggested that serial CT scan are valuable for evaluating the neurological status and the level of mental deterioration. Sub-acute and acute CO intoxication is reported to be with globus pallidus necrosis, demyelination, white-matter lesions with and necrosis of hippocampus.

Conclusion

As a conclusion, we state that a suspicion of CO intoxicity a detailed evaluation is lifesaving. Cardiac monitoring, intubation and 100% oxygen applications, elaborate physical and radiological evaluations are mandatory. Serial CT scan of the brain can also present specific and enlightening findings in CO intoxicity cases.

Funding

None.

Conflict of Interest

None.

References

1. Carbon monoxide related deaths United States, 1999-2004. MMWR Morb Mortal Wkly Rep. 2007; 56(50): 1309-12.
2. Mefkur B, Umutoglu T, Topuz U, et al. Opioid-free total intravenous anesthesia with propofol, dexmedetomidine and lidocaine infusions for laparoscopic cholecystectomy: a prospective, randomized, double-blinded study. Brazilian Journal of Anesthesiology. 2015;3:191-9. https://doi.org/10.1016/j.bjane.2014.05.001
3. Bourtros AR, Hoyt JL. Management of carbon monoxide poisoning in the absence of hyperbaric oxygenation chamber. Crit Care Med.1976; 4(3): 144-7. https://doi.org/10.1097/00003246-197605000-00003
4. Gorman D, Drewry A, Huang YL, Sames C. The clinical toxicology of carbon monoxide. Toxicology. 2003;187(1):25-38. https://doi.org/10.1016/S0300-483X(03)00005-2
5. Ilano AL, Raffin TA. Management of carbon monoxide poisoning. Chest. 1990;97(1):165-9. https://doi.org/10.1378/chest.97.1.165
6. Raub JA, Benignus VA. Carbon monoxide and the nervous system. Neurosci Biobehav Rev. Dec 2002; 26(8): 925-40. https://doi.org/10.1016/S0149-7634(03)00002-2
7. Topuz U, Salihoglu G, Banu U, et al. The Effects of Different Oxygen Concentrations on Recruitment Maneuver During General Anesthesia for Laparoscopic Surgery. Surgical Laparoscopy Endoscopy & Percutaneous Techniques: October 2014;5:410–3. https://doi.org/10.1097/SLE.0000000000000048
8. Vieregge P, Klostermann W, Blümm RG, Borgis KJ. Carbon monoxide poisoning: clinical, neurophysiological, and brain imaging observations in acute disease and follow-up. J Neurol. 1989;236(8):478-81. https://doi.org/10.1007/BF00328511
9. Salihoglu Z, Yildirim D, Sener KG, et al. Evaluation of Intravenous Paracetamol Administration on Postoperative Pain and Recovery Characteristics in Patients Undergoing Laparoscopic Cholecystectomy. Surgical Laparoscopy Endoscopy & Percutaneous Techniques:2009;19(4):321-3. https://doi.org/10.1097/SLE.0b013e3181b13933
10. Silver DAT, Cross M, Fox B, et al. Computed tomography of the brain in acute carbon monoxide poisoning. Clinical Radiology. 1996;7:480-3. https://doi.org/10.1016/S0009-9260(96)80186-3

©Copyright 2019 by Çukurova Anestezi ve Cerrahi Bilimler Dergisi - Available online at http://dergipark.gov.tr/jocass